



CLINICAL STUDY

CONTRIBUTION OF HIGH-RESOLUTION COMPUTED TOMOGRAPHY TO THE DIAGNOSIS OF OTOSCLEROSIS

Ayça Başkadem YILMAZER , MD Elif AKSUNGUR, MD 

SBÜ Prof Dr Cemil Taşcıoğlu Hastanesi, Kulak Burun Boğaz Hastalıkları, İstanbul, Turkey

SUMMARY

Objective: To demonstrate the contribution of high-resolution computed tomography (HRCT) images obtained preoperatively to diagnosing patients who underwent stapedotomy with a prediagnosis of otosclerosis in our clinic.

Materials and Methods: We obtained data on 77 patients who underwent an exploratory tympanotomy with a prediagnosis of otosclerosis. Preoperatively received HRCT images and audiological examinations (pure-tone audiometry and tympanometry) were retrospectively analysed.

Results: HRCT images and audiological examinations of 29 patients that met the study's criteria were documented. According to Marshall's Classification on otosclerotic foci at HRCT, it was found that 55.2% (n=16) of patients had an otosclerosis focus on CT images, i.e., the sensitivity rate of the HRCT on the diagnosis of otosclerosis is 55.2%, statistically. Carhart's Notch was present in 37.9% of the radiologically positive patients (n=11). No statistically significant correlation was found between otosclerotic foci on HRCT and Carhart's Notch on an audiogram (p: 0,624).

Conclusion: While HRCT has low diagnostic accuracy in diagnosing otosclerosis, preoperatively obtained HRCT imaging is still essential for differential diagnosis and evaluation of anatomical variations.

Keywords: Otosclerosis; High resolution computed tomography; Sensitivity

YÜKSEK ÇÖZÜNÜRLÜKLÜ BİLGİSAYARLI TOMOGRAFİNİN OTOSKLEROZ TANISINA KATKISI ÖZET

Amaç: Kliniğimizde otoskleroz ön tanısıyla opere edilen hastalarda, ameliyat öncesi çekilen yüksek çözünürlüklü bilgisayarlı tomografinin (YÇBT) tanıya katkısının gösterilmesi amaçlandı.

Yöntem ve Gereçler: Otoskleroz ön tanısıyla timpanostomi yapılmış 77 hasta verisine ulaşıldı. Preoperative çekilen YÇBT görüntülemeleri ve radyolojik değerlendirmeler (saf ses odyometri ve timpanogram) incelendi.

Bulgular: Dahil edilme kriterlerini karşılayan 29 hastanın preoperative çekilmiş YÇBT görüntülemeleri ve radyolojik değerlendirmeleri analiz edildi. Marshall'ın YÇBT'de otosklerotik odak hakkındaki sınıflandırmasına göre, YÇBT görüntülemelerinde hastaların %52,2'sinde (n=16) otosklerotik odak gözlemlendi. YÇBT'nin otoskleroz tanısındaki duyarlılığının istatistiksel olarak %52,2 olduğu görüldü. Radyolojik olarak otoskleroz pozitif olan hastaların %37,9'unda (n=11) Carhart'ın çentiği odyogramda pozitif görüldü. Radyolojik olarak otoskleroz bulunmasının Carhart'ın çentiğinin odyogramda görülmesi ile arasında istatistiksel olarak ilişki gözlemlenmedi (p=0,624).

Sonuç: Otoskleroz tanısına katkısı düşük olduğu halde, ameliyat öncesinde ayırıcı tanı ve anatomik varyasyonların değerlendirilmesi için YÇBT görüntülemesi önem taşımaktadır.

Anahtar Sözcükler: Otoskleroz; Yüksek çözünürlüklü bilgisayarlı tomografi; Duyarlılık

INTRODUCTION

Otosclerosis is characterised by pathologically increased bone remodelling in the otic capsule, i.e., abnormal destruction and reconstruction. This can occur to varying degrees, including fixation of the stapes footplate and complete resorption of the cochlea.^{1,2} The

gold standard for diagnosis is histopathologic confirmation.²⁻⁴ The presence of otosclerosis may be suspected by combining physical examination and laboratory findings. Patients apply to the clinic with complaints of difficulty in hearing. The tympanic membrane is usually intact and mobile in physical examination, performed with the Valsalva manoeuvre. Rarely a blue-red colour of reflux can be obtained from the promontory (Schwartz's sign).⁵ It can cause conductive and sensorineural hearing loss.^{1,6} A Carhart's notch can be observed on the audiogram at 2000 Hz. The absence of stapedial reflexes strengthens the diagnosis in the Acoustic Reflex test.^{7,8} An exploratory tympanotomy approaches the diagnosis by observing that the stapes footplate is fixed.^{9,10}

Corresponding Author: Ayça Başkadem YILMAZER MD
SBÜ Prof Dr Cemil Taşcıoğlu Hastanesi, Kulak Burun Boğaz
Hastalıkları, İstanbul, Turkey, E-mail: aycabaskadem@hotmail.com

Received: 11 August 2023, revised for: 25 August 2023,
accepted for publication: 26 August 2023

Cite this article: Yılmaz A. B. Aksungur E., Contribution Of
High-Resolution Computed Tomography To The Diagnosis Of
Otosclerosis. KBB-Forum 2023;22(3):183-187



Although high-resolution computed tomography (HRCT) preoperatively obtained is always helpful in ear surgery for making a differential diagnosis and visualising anatomical variants, its sensitivity in the diagnosis of otosclerosis is still controversial. Various sources have found Different sensitivity rates in a wide range of 47.1-91.3%.¹¹⁻¹⁴ This study aims to demonstrate the contribution of HRCT images obtained preoperatively to diagnosing patients who underwent stapedotomy with a prediagnosis of otosclerosis in our clinic.

MATERIAL and METHODS

The study was conducted in the otorhinolaryngology clinic of a tertiary care hospital. We obtained data on 77 patients who underwent an exploratory tympanotomy with a prediagnosis of otosclerosis between 2017 and 2018. Preoperatively obtained HRCT scans and audiological examinations (pure-tone audiometry and tympanometry) were retrospectively analysed.

The following were the criteria for inclusion: on patients aged 18-65 years, HRCT imaging was performed and reported in our hospital, audiological evaluations were performed in our clinic, stapedotomy was completed in one ear, stapedotomy was achieved only because the stapes footplate was fixed, and a piston was inserted. The following criteria for exclusion: history of previous ear surgery, ear discharge, head trauma, and congenital hearing loss.

HRCT images preoperatively obtained of patients with otosclerosis who had surgery confirmed their diagnosis were analysed, and their reports were documented. According to Marshall's classification system, Otosclerosis was classified on HRCT (Table-1).¹⁵ All preoperative images were obtained in high resolution in the transverse plane with 128 sections and 0.67 mm thickness using Multi-sliced CT SOMATOM Definition Edge (Siemens Medical Solutions, Malvern, PA, USA) and uploaded to the system (PACS) at 1600 Hf unit window width and 400 Hf unit window centre (Figure 1a-c).

The local institutional review board approved this study. The ethical approval date and number of the study is 19/04/2021-170.

Statistical Analysis

To analyse the data, SPSS® 15.0 for Windows Programme was used. Descriptive statistical methods (mean, median, standard deviation "SD", frequency, percentage, minimum, and maximum) were used to evaluate the data. Pearson's chi-squared test was used to compare the qualitative variables. Statistical significance was accepted as $p < 0.05$.

RESULTS

HRCT images and audiological examinations of 29 patients who met the inclusion criteria were documented in the study. Bilateral otosclerosis was suspected in 25 patients, but they had all recently had a stapedotomy in one ear. The mean age of the patients was $35.37 + 10.65$ years (min-max: 18-62). Of the patients, 44.8% (n=13) were female, and 55.2% (n=16) were male.

Preoperative HRCT images were analysed according to Marshall's classification system. Thirteen (44.8%) HRCT images showed grade-0 otosclerosis, and 16(55.2%) HRCT images showed grade-1 otosclerosis. No evidence of grade-2 or higher otosclerosis was observed. Thus, it is found that the sensitivity rate of the HRCT on the diagnosis of otosclerosis is 55.2%, statistically.

The preoperative tympanometric evaluation revealed type-As tympanograms in all patients. Twenty-five patients had no acoustic reflexes bilaterally, and four patients had no unilaterally. The pure-tone audiometry results showed a mean airway threshold of $47.51 + 5.25$ dB and a mean bone conduction threshold of $14.55 + 4.22$ dB.

Carhart's Notch was observed at 1000 or 2000 Hz in 72.4% of patients (n=21). Carhart's Notch was present in 37.9% of the radiologically positive patients (n=11). No statistically significant correlation was found between otosclerotic foci on HRCT and Carhart's Notch on the audiogram (Pearson's chi-square test, $p: 0,624$).



Table 1. Marshall's Classification of Disease on Computed Tomography Scanning

| Marshall's Classification of Disease on Computed Tomography Scanning | |
|--|---|
| Grade | Radiologic signs of otosclerosis |
| 0 | Normal |
| 1 | Only fenestral involvement |
| 2 | Patchy localised retro-fenestral disease with or without fenestral involvement |
| 2a | Basal cochlear |
| 2b | Apical or mid cochlear |
| 2c | Apical, mid, or basal cochlear |
| 3 | Diffuse confluent retro-fenestral involvement with or without fenestral involvement |

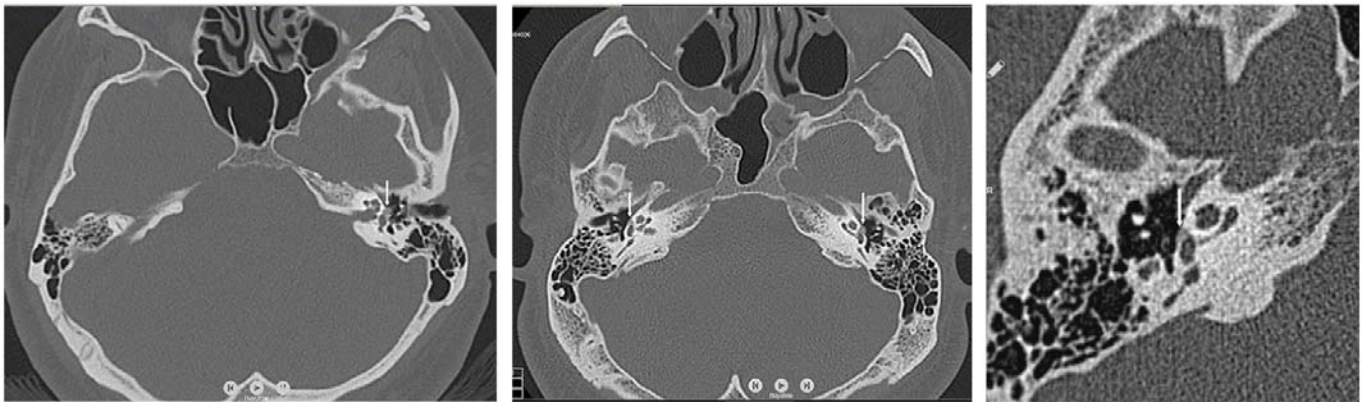


Figure 1a, b, c: Otosclerotic foci in different temporal HRCT images; white arrows show the foci

DISCUSSION

Studies show that the sensitivity level of HRCT varies over a wide range. Shin et al. investigated 437 HRCT images in 2001 and discovered that the sensitivity of tomography in the diagnosis of otosclerosis was 91.3%.¹¹ Another study reported that otosclerosis findings obtained from 44 HRCT images confirmed the diagnosis with a sensitivity rate of 85%.¹⁶ Maxwell et al. analysed 68 HRCT images for otosclerosis in 2020 and reported a CT

sensitivity of 47.1%.¹⁴ In our study, the sensitivity of HRCT was found to be 55.2% in patients whose diagnosis was confirmed by surgery. It is observed that this rate has decreased in recent years. Although the evaluation has always been performed with HRCT, the decrease in sensitivity rate should be investigated. In a study by Naumann et al., a group of otosclerosis patients were treated with fluoride therapy, and HRCT was performed six months later. Although no difference was observed in hearing levels compared to untreated



patients, otosclerosis findings on HRCT were significantly lower.¹⁶ This suggests that although increasing the consumption of fluoride-rich foods and fluids in patients with suspected otosclerosis, as highly recommended by physicians nowadays, may not be beneficial for improving hearing, it may improve radiologic findings and, thus histopathologic findings, which may decrease the sensitivity of HRCT in diagnosing otosclerosis. Different studies may be conducted to investigate the reasons for the gradual decrease in the sensitivity rate of HRCT in diagnosing otosclerosis.

Evaluation of otosclerosis on CT imaging was performed according to the classification system described by Marshall et al.¹⁵. Accordingly, the images of our patients were either grade 0 or grade 1. The reason for finding no otosclerotic foci of grade 2 or higher in our study may be that we did not perform otosclerosis surgery in patients with abnormal bone conduction hearing levels, i.e., those who were thought to have developed cochlear otosclerosis. In our study, the patients only had undergone otosclerosis surgery.

In literature, to the best of our knowledge, few studies have evaluated the degree of hearing loss and the presence of radiologic findings. Naumann et al. assessed the relationship between the air-bone gap and the extent of otosclerotic focus on HRCT. They reported that the air-bone gap increased as the radiologic fenestral otosclerotic focus widened.¹⁶ Marx et al. also showed a similar relationship between hearing and radiologic focus.¹² Our study could not examine this relationship because the osteosclerotic focus measure was not calculated.

The Carhart's notch, as it is known, strengthens the diagnosis of otosclerosis, but it is not found in every patient. The relationship between the presence of Carhart's notch and the presence of radiologic focus was evaluated in our study, but no association was found.

The study's limitations are the small number of patients and the retrospective nature of the study. Prospective studies with a more significant number of patients may contribute more to the literature. Moreover, to evaluate not

only the sensitivity but also the specificity of HRCT on the diagnosis of otosclerosis, a control group may be included in new studies.

In conclusion, while HRCT has low diagnostic accuracy in diagnosing otosclerosis, preoperatively obtained HRCT imaging is still essential for differential diagnosis and evaluation of anatomical variations.

Financial disclosure statement: None of the authors have any competing interests. This research received no specific grant from funding agencies in the public, commercial, or not-for-profit sectors.

REFERENCES

1. Chole RA, McKenna M. Pathophysiology of otosclerosis. *Otol Neurotol* 2001;22(2):249-257.
2. Parahy C, Linthicum FH Jr. Otosclerosis and otospongiosis: clinical and histological comparisons. *Laryngoscope* 1984;94(4):508-512.
3. Karosi T, Csomor P, Petkó M, Liktó B, Szabó LZ, Pytel J, Jóri J, Sziklai I. Histopathology of nonotosclerotic stapes fixations. *Otol Neurotol* 2009;30(8):1058-1066.
4. Iyer PV, Gristwood RE. Histopathology of the stapes in otosclerosis. *Pathology* 1984;16(1):30-38.
5. Cureoglu S, Baylan MY, Paparella MM. Cochlear otosclerosis. *Curr Opin Otolaryngol Head Neck Surg* 2010;18(5):357-362.
6. Swartz JD, Faerber EN, Wolfson RJ, Marlowe FI. Fenestral otosclerosis: significance of preoperative CT evaluation. *Radiology* 1984;151(3):703-707.
7. Gredilla Molinero J, Mancheño Losa M, Santamaría Guinea N, Arévalo Galeano N, Grande Báez M. Update on the imaging diagnosis of otosclerosis. *Radiologia* 2016;58(4):246-256.
8. Lagleyre S, Sorrentino T, Calmels MN, Shin YJ, Escudé B, Deguine O, Fraysse B. Reliability of high-resolution CT scan in diagnosis of otosclerosis. *Otol Neurotol* 2009;30(8):1152-1159.
9. Wegner I, van Waes AM, Bittermann AJ, Buitinck SH, Dekker CF, Kurk SA, Rados M, Grolman W. A Systematic Review of the Diagnostic Value of CT Imaging in Diagnosing Otosclerosis. *Otol Neurotol* 2016;37(1):9-15.
10. Lee TL, Wang MC, Lirng JF, Liao WH, Yu EC, Shiao AS. High-resolution computed tomography in the diagnosis of otosclerosis in Taiwan. *J Chin Med Assoc* 2009;72(10):527-532.
11. Shin YJ, Fraysse B, Deguine O, Cognard C, Charlet JP, Sévely A. Sensorineural hearing loss and otosclerosis: a clinical and radiologic survey of 437 cases. *Acta Otolaryngol* 2001;121(2):200-204.
12. Marx M, Lagleyre S, Escudé B, Demeslay J, Elhadi T, Deguine O, Fraysse B. Correlations between CT scan findings and hearing thresholds in otosclerosis. *Acta Otolaryngol* 2011;131(4):351-357.



13. Wycherly BJ, Berkowitz F, Noone AM, Kim HJ. Computed tomography and otosclerosis: a practical method to correlate the sites affected to hearing loss. *Ann Otol Rhinol Laryngol* 2010;119(12):789-794.
14. Maxwell AK, Shokry MH, Master A, Slattery WH 3rd. Sensitivity of high-resolution computed tomography in otosclerosis patients undergoing primary stapedotomy. *Ann Otol Rhinol Laryngol* 2020;129(9):918-923.
15. Marshall AH, Fanning N, Symons S, Shipp D, Chen JM, Nedzelski JM. Cochlear implantation in cochlear otosclerosis. *Laryngoscope* 2005;115(10):1728-1733.
16. Naumann IC, Porcellini B, Fisch U. Otosclerosis: incidence of positive findings on high-resolution computed tomography and their correlation to audiological test data. *Ann Otol Rhinol Laryngol* 2005;114(9):709-716.