



CLINICAL STUDY

THE EVALUATION OF RESIDUAL ADENOID TISSUE AT THE END OF CONVENTIONAL CURETTAGE ADENOIDECTOMY

Yusuf DUNDAR¹, MD; Fatih AKCAN², MD; Nergis SALMAN², MD; Gül SOYLU³, MD; Güleser SAYLAM⁴, MD; Ali ÖZDEK⁵, MD

¹Ishakoğlu Çayeli Devlet Hastanesi, KBB, Rize, Türkiye ²Ankara Çocuk Hematoloji Onkoloji Hastanesi, KBB, Ankara, Türkiye ³Mustafa Kemal Üniversitesi, KBB, Hatay, Türkiye ⁴Dışkapı Yıldırım Beyazıt Eğitim ve Araştırma Hastanesi, KBB, Ankara, Türkiye ⁵Karabük Üniversitesi, KBB, Karabük, Türkiye

SUMMARY

Background: Adenoidectomy is one of the most common surgical operations in daily otolaryngology practice. Conventional curettage adenoidectomy guided by digital palpation is a simple and quick procedure that has already been in use for a long time. Conventional curettage adenoidectomy carries a high risk of recurrence unless done by well-experienced surgeons. Some authors suggest that conventional curettage adenoidectomy resulted in the residual tissue up to 50 % of all patients. To determine the residual adenoid tissue by mirror and naso-endoscopic assessment in patients undergoing conventional curettage adenoidectomy was the aim in this study.

Material and Methods: 50 adenoidectomy operations were included in this study between January 2013 and July 2013. The history of previous surgery, anatomic anomaly and acute infection was accepted as an exclusion criterion. The narrowest segment and adenoid tissue volume were assessed with digital palpation, mirror and naso-endoscopic examination just before the surgery. Conventional curettage adenoidectomy with digital palpation was used in all patients as the operation technique. The residual adenoid tissues were assessed with trans-oral mirror and trans-nasal nasendoscopic examination at the end of the operation. Residual tissue size and localization were measured and compared with each other.

Results: Pre-surgical nasal endoscopy and mirror examination revealed that the choana was narrowed by the adenoid tissue at an average of 81.1 % (range: 30-95 %). Residual adenoid tissue was detected in 24 (48 %) patients by mirror and naso-endoscopic examination at the end of operation. The incomplete removing of adenoid tissue was detected in nasopharyngeal roof (34 %), posterior pharyngeal wall (10 %) and Eustachian tube opening (6 %).

Conclusion: Conventional curettage adenoidectomy misses the residual adenoid tissue in nasopharyngeal roof, posterior pharyngeal wall, eustachian tube opening. Nasopharyngeal exploration is essential in conventional adenoidectomy. Trans-oral mirror examination or nasoendoscopy can be used for evaluation of residual tissue. Mirror examination may be an effective and easier way in small children and resident training.

Keywords: Adenoidectomy, Endoscope assisted adenoidectomy, Mirror assisted adenoidectomy

KONVANSİYONEL KÜRETAJ ADENOİDEKTOMİ SONRASI REZİDÜ ADENOİD DOKUNUN DEĞERLENDİRİLMESİ

ÖZET

Amaç: Adenoidektomi kulak burun boğaz cerrahisi pratiğinde en çok uygulanan girişimlerdendir. Palpasyon yöntemi ile yapılan konvansiyonel adenoidektomi uzun süreden beri uygulanagelen basit ve hızlı bir adenoidektomi yöntemidir. Konvansiyonel adenoidektomi usta ellerde uygulanmadığı sürece yüksek rekürrens riski taşır. Konvansiyonel adenoidektomi sonrası rezidü oranların % 50'lere yakın olduğunu savunan yazarlar bulunmaktadır. Çalışmamızda konvansiyonel adenoidektomi yapılan hastalarda rezidü adenoid dokusunun ayna ve endoskopi yöntemleri ile değerlendirilmesi amaçlanmıştır.

Gereç ve Yöntem: Çalışmaya 01.01.2013-01.07.2013 tarihleri arasında konvansiyonel adenoidektomi yapılan 50 olgu dahil edildi. Daha önce geçirilmiş cerrahi öyküsü, anatomik anomali mevcudiyeti, akut enfeksiyonu olan olgular çalışmaya dahil edilmedi. Nazofarenkste en dar segment ve adenoid doku miktarı cerrahiden hemen önce dijital palpasyon, ayna ve endoskopik yöntemlerle değerlendirildi ve kayıt altına alındı. Tüm hastalara cerrahi yöntem olarak konvansiyonel adenoidektomi tekniği uygulandı. Rezidü adenoid dokusu operasyonun sonunda trans-oral ayna ve trans-nazal endoskopik yöntemlerle değerlendirildi. Rezidü dokunun lokalizasyonu ve miktarı ölçülerek karşılaştırıldı.

Sonuç: Cerrahi öncesi değerlendirmelerde nazofarenksin en dar segmenti ortalama % 81.1 (% 30-95) olarak koana olarak ölçüldü. Konvansiyonel adenoidektomi sonrası hastaların 24'ünde (%48) rezidü adenoid dokusu saptandı. Rezidü lokalizasyonları ise sıklıkla nazofarengeal çatı (% 34), posterior farengeal duvar (%10) ve östaki tüpü ağzı (% 6) idi.

Tartışma: Konvansiyonel küretaj adenoidektomi nazofarengeal çatı, posterior farenks duvarı ve tuba ağzında rezidü adenoid doku kalmasına neden olabilir. Nazofarengeal eksplorasyon konvansiyonel küretaj adenoidektomi için çok önemlidir. Trans-oral ayna yöntemi ya da trans-nazal endoskopik yöntem nazofarengeal eksplorasyon için kullanılabilir. Trans-oral ayna yöntemi küçük çocuklarda ve asistan eğitiminde kullanılabilir. Trans-oral ayna yöntemi küçük çocuklarda ve asistan eğitiminde kullanılabilir.

Anahtar Sözcükler: Adenoidektomi, Endoskop aracılı adenoidektomi, ayna aracılı adenoidektomi

Corresponding Author: Yusuf Dunder MD Ishakoğlu Çayeli Devlet Hastanesi, KBB, Rize, Türkiye, E-mail: ysfndr@gmail.com

Received: 25 July 2014, revised for: 25 November 2014, accepted for publication: 26 November 2014

INTRODUCTION

Adenoid is a lymphoid tissue forming a part of Waldeyer ring, which was described by Meyer¹. Adenoidectomy is a surgical technique that consists of removing the hypertrophied lymphatic tissue which obstructs the rhinopharynx. Adenoidectomy is



one of the most common procedures in pediatric cases, either alone or in conjunction with tonsillectomy or inserting ventilation tubes². Conventional curettage adenoidectomy is a widely used technique in daily practice, which was first described in 1885¹. This technique mainly depends on digital palpation for evaluating the residual tissue. Conventional curettage adenoidectomy carries a high risk of recurrence unless done by well-experienced surgeons^{3,4}. The main problem is blind working in this technique. Some authors suggest that conventional curettage adenoidectomy resulted in the residual tissue in up to 50 % of all patients^{5,6}. Several adenoidectomy techniques have been described in literature which was trying to reduce recurrence risk. An indirect trans-oral mirror guided adenoid curettage with 'St. Clair Thompson Curette' is a simple and quick procedure that has already been in use for a long time. Trans-oral or trans-nasal video-assisted adenoidectomy is a novel method with good visualization. Each technique has its advantages and disadvantages.

In this paper, we analyzed the efficiency of conventional curettage adenoidectomy by trans-oral mirror and trans-nasal endoscopic examination.

MATERIAL and METHODS

Prospective study of 50 children who underwent conventional curettage adenoidectomy from January 2013 to July 2013. The study center is a tertiary referral center and each pediatric otolaryngologist performs average 300 adenoidectomy operations in a year. The operations in this study were performed by two well experienced surgeons. The children's ages was between 24 months to 13 years, 31 being males (62 %) and 19 females (38 %). These patients had symptoms of nasal obstruction, snoring, apnea and hearing loss. Informed consents were obtained from parents of the patients before the inclusion which was approved by the local ethics committee.

Routine ENT examination and history taking were performed prior to surgery. Pediatric consultation was done to exclude any other medical problems, additional to routine lab investigations. Previously adenoidectomy history and congenital anomaly history like cleft palate were accepted as exclusion criteria.

Patients were operated under general anesthesia with oral endotracheal intubation. A Boyle-Davis mouth gag was used to open the mouth in Rose's position with a shoulder roll. Subsequently, patients were cleaned and draped. The 00 Hopkins 4 mm nasal endoscope is placed to nose and adenoid

mass identified. The adenoid size and localization were noted. Soft palate retracted anteriorly by a retractor. Then conventional curettage adenoidectomy was performed with digital palpation by using St. Claire Thompson forceps. The suction was used to clear the operation field during the surgery. Digital examination was performed to make sure complete removal. At the end of the procedure, a pack of gauze was inserted into nasopharyngeal area for bleeding control. Nasopharyngeal packing was removed and saline irrigation was performed a few minutes later. Nasopharyngeal exploration was done by indirect oro-pharyngeal mirror examination and nasal-endoscopic examination at the end of the operation. Residual adenoid tissue size and localization were identified and noted in both exploration techniques. These examination methods were compared with each other.

The efficiency of both explorative techniques was compared by SPSS 17 software program.

RESULTS

The study sample (n: 50) had 31 male and 19 female patients with the mean age of 28 months at the time of surgery (Table 1). The mean choanal obstruction rate was 81.1 % due to adenoid hypertrophy with the range of 30 to 95 %. 24 of 50 patients (48 %) had residual adenoid tissue at the end of the conventional curettage adenoidectomy. The anatomic localizations of the residual adenoid tissue were nasopharyngeal roof in 16 patients (32 %), torus tubarius in 3 patients (6 %), posterior pharyngeal wall in 4 patients (8 %) and nasopharyngeal roof + posterior pharyngeal roof in 1 patient (2 %) (Table 1).

The indirect trans-oral mirror examination catches the 4 out of 24 residual tissues (83.3 %). This technique missed 4 residual adenoid mass, 2 were in nasopharyngeal roof and 2 were in tubal opening (Figure 1).

The trans-nasal endoscopic examination catches the 5 out of 24 residual tissues (79.1 %). This technique missed 5 residual adenoid mass; 3 were in nasopharyngeal roof, 1 was in posterior pharyngeal wall and 1 was in nasopharyngeal roof + posterior pharyngeal wall (Figure 1).

There was no significant difference between the two examination methods ($p > 0.05$).

The trans-nasal endoscopic examination had manipulation difficulties in 4 cases. These children were under 3 years old. This difficulty was mainly related with small anatomic structures. Endoscopic



imaging and manipulating are not easy in small children.

Table 1: Patient and operation technique characteristics.

Patient	Sex	Adenoid Size	Residual Tissue	Localization	Mirror	Endoscope	Endoscopic Vizualization
1	female	70					Good
2	female	85	yes	Roof	-	+	Good
3	female	95					Good
4	female	60	yes	Posterior Wall	+	-	Good
5	male	95					Good
6	male	90					Good
7	female	80					Good
8	male	80					Good
9	female	90	yes	Posterior Wall	+	+	Good
10	female	60	yes	Roof	+	+	Good
11	female	80	yes	Roof	+	+	Good
12	female	80	yes	Roof	+	+	Good
13	female	60					Good
14	male	80					Good
15	male	70					Good
16	female	95	yes	Roof	+	-	Good
17	female	90	yes	Tubal Opening	-	+	Good
18	male	30					Good
19	male	70					Good
20	male	60					Good
21	male	95	yes	Roof	-	+	Good
22	male	80					Good
23	female	80	yes	Roof	+	+	Poor
24	male	90					Good
25	male	95	yes	Roof	+	+	Good
26	male	70	yes	Posterior Wall	+	+	Good
27	male	80					Good
28	male	90	yes	Roof	+	+	Good
29	male	90	yes	Roof	+	+	Poor
30	male	95					Good
31	male	90					Good
32	female	95					Good
33	male	80	yes	Roof	+	+	Good
34	female	90	yes	Roof	+	+	Good
35	female	60	yes	Roof	+	+	Good
36	male	80					Poor
37	male	40	yes	Roof + Post. Wall	+	-	Poor
38	male	80					Good
39	male	90	yes	Roof	+	+	Good
40	female	95	yes	Posterior Wall	+	+	Good
41	male	90					Good
42	male	95					Good
43	female	80	yes	Tubal Opening	+	+	Good
44	male	85					Good
45	male	95					Good
46	male	95	yes	Tubal Opening	-	+	Good
47	female	70	yes	Roof	+	-	Good
48	male	90					Good
49	male	90					Good
50	male	80	yes	Roof	+	-	Good

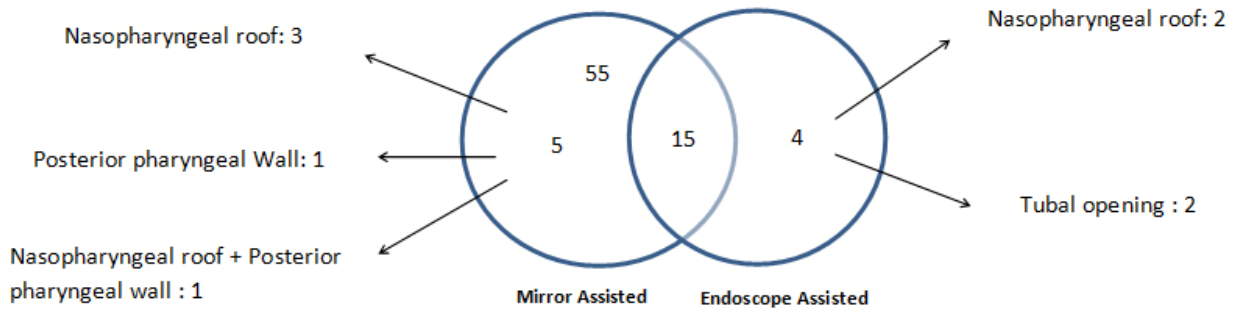


Figure 1: Comparison of residual adenoid tissue number and localization.

DISCUSSION

Adenoidectomy is one of the most common surgical operations in daily otolaryngology practice. Conventional curettage adenoidectomy guided by digital palpation is a simple and quick procedure that has already been in use for a long time. This technique carries the risk of blind working in operation area. The complications of conventional curettage adenoidectomy are bleeding, nasopharyngeal stenosis, eustachian tube stenosis and leave behind obstructing tissue². Bleeding, nasopharyngeal stenosis and eustachian tube stenosis are relatively rare complications; however residual adenoid tissue is very common. Some studies have been reported with the residual adenoid tissue up to 50 % in conventional curettage adenoidectomy^{5,7}. Our results were revealed with 48 % residual adenoid tissue at the end of the conventional adenoidectomy. Residual adenoid tissues may cause of recurrent nasal obstructions. A recently published study indicates the proportion of median percentage of residual adenoid tissue to total adenoid tissue is 19.98 % (Range: 3.22-50 %) ⁵. Permanent nasal obstruction symptoms are most probably associated with residual adenoid tissue rates as a result of blind working⁸.

Many surgical techniques and instruments have been utilized throughout adenoidectomies⁹. The techniques of adenoidectomy can be listed with cold curettage, bipolar adenoidectomy, power assisted adenoidectomy, suction diathermy ablation and radiofrequency adenoidectomy^{10, 11}. Cold curettage technique is the most commonly used technique. Each technique has its advantages and disadvantages. Cold curettage is a relatively safe and easy method in experienced hands. The main problem is residual disease and recurrence in cold curettage. Our subjects were operated on by well experienced surgeons who

perform an average of 300 adenoidectomy per year. Nevertheless, 48 % subjects had residual adenoid tissues at the end of the conventional curettage adenoidectomy.

Recurrence rate of conventional curettage adenoidectomy is more than six times of endoscope assisted adenoidectomy¹². The novel researchers are focusing to solve recurrence problem. Many guided techniques were described to reduce recurrence rates^{2,7,13,14}, and ¹⁵. The guided techniques improve the visualization of operating area and also help to avoid Eustachian tube injury¹³. Trans-nasal and trans-oral way can be used to explore nasopharyngeal area during surgery. Indirect visualization of adenoid tissue by laryngeal mirror and headlight is the most common used method in trans-oral way. This technique is very easy and effective in experienced hands^{3,4}. Trans-oral endoscope assisted adenoidectomy is another visualization method of nasopharynx which can be combined to conventional curettage or power assisted techniques^{15,16}. Trans-oral endoscope assisted technique has good outcomes with relatively low complication rates^{13,17,18}. Trans-nasal Hopkins 00 telescope can be used for exploration of nasopharyngeal area². This technique also can be combined to conventional technique or power assisted techniques. Trans-nasal approach is a relatively difficult way due to small anatomic structures¹⁹. In our study we had the manipulation difficulties in four subjects, all of them were under 3 years old. Turbinate edema, bleeding from operation area and small anatomical structures may cause the inadequate exploration.

Adenoidectomy is the most common surgical procedure in pediatric cases. Surgeons mostly start to learn principles of ENT surgeries with adenoidectomy. Conventional curettage



adenoidectomy is the first surgical experiences of many otolaryngologists. Blind working and curettage with digital palpation is not easy to learn at the beginning of otolaryngology training. Conventional curettage adenoidectomy with digital palpation is not right way to start teaching of adenoidectomy. Conventional way mostly depends on imagination of blind area. This situation may cause the complications in in-experienced hands. Endoscope assisted methods may help improve training outcomes and efficiency of surgery. However using endoscope assisted methods need experience in endoscopic sinus surgery. In addition, setting of the endoscopic imaging equipment needs more time which leads to prolonged surgeries. Trans-oral indirect mirror examination is a very easy and effective way to explore the nasopharyngeal area. It doesn't need any additional equipment except laryngeal mirror. This technique doesn't need any setting time in contrast to endoscope assisted techniques. This technique doesn't need any endoscopic sinus surgery experience thus it can be used at the beginning of resident training.

This study was designed to evaluate the efficiency of conventional curettage adenoidectomy by different exploration techniques.

CONCLUSION

Digital palpation of nasopharynx is not an effective way to check residual adenoid tissue. The visualization methods are strongly recommended to improve surgical outcomes. Indirect trans-oral mirror examination or trans-nasal endoscopic examination can be used for this issue. Trans-oral indirect mirror examination may be superior due to simplicity of needed equipment and practicability for young surgeons.

Acknowledgments:

All authors thank to Jes Millsaps for her English revisions.

REFERENCES

1. Thornval A. Wilhelm Meyer and the adenoids. Arch Otolaryngol Head Neck Surg. 1969; 90:383.
2. Somani SS, Naik CS, Bangad SV. Endoscopic adenoidectomy with microdebrider. Indian J Otolaryngol Head Neck Surg. 2010; 62:427-431.
3. Elluru RG, Johnson L, Myer CM. III Electrocautery adenoidectomy compared with curettage and power-assisted methods. Laryngoscope. 2002; 112:23-25.
4. Stanislaw P, Jr., Koltai PJ, Feustel PJ. Comparison of power-assisted adenoidectomy vs adenoid curette adenoidectomy. Archives of Otolaryngology—Head and Neck Surgery. 2000; 126:845-849.
5. Ark N, Kurtaran H, Ugur KS, Yilmaz T, Ozboduroglu AA, Mutlu C. Comparison of adenoidectomy methods: examining with digital palpation vs. visualizing the placement of the curette. Int J Pediatr Otorhinolaryngol. 2010; 74:649-651.
6. Regmi D, Mathur NN, Bhattarai M. Rigid endoscopic evaluation of conventional curettage adenoidectomy. J Laryngol Otol. 2011; 125:53-58.
7. Pagella F, Matti E, Colombo A, Giourgos G, Mira E. How we do it: a combined method of traditional curette and power-assisted endoscopic adenoidectomy. Acta Otolaryngol. 2009; 129:556-559.
8. Chisholm EJ, Lew-Gor S, Hajioff D, Caulfield H. Adenoid size assessment: a comparison of palpation, nasendoscopy and mirror examination. Clin Otolaryngol. 2005; 30:39-41.
9. Clemens J, McMurray J. S, Willging J. P. "Electrocautery versus curette adenoidectomy: comparison of postoperative results," International Journal of Pediatric Otorhinolaryngology. 1998; 43:115-122.
10. Owens D, Jaramillo M, Saunders M. Suction diathermy adenoid ablation. J Laryngol Otol 2005; 119:34-35.
11. Wong L, Moxham JP, Ludemann JP. Electrosurgical adenoid ablation. J Otolaryngol 2004; 33:104-106.
12. Abdel-Aziz M. Endoscopic nasopharyngeal exploration at the end of conventional curettage adenoidectomy. Eur Arch Otorhinolaryngol. 2012; 269:1037-1040.
13. El-Badrawy A, Abdel-Aziz M. Transoral endoscopic adenoidectomy. Int J Otolaryngol. 2009; 2009:949315.
14. Zainea V. Conventional curettage adenoidectomy versus endoscopic assisted adenoidectomy. Maedica (Buchar). 2011; 6:328-329.
15. Wan YM, Wong KC, Ma KH. Endoscopic-guided adenoidectomy using a classic adenoid curettage: a simple way to improve adenoidectomy. Hong Kong Med J. 2005; 11:42-44.
16. P. J. Koltai, A. S. Kalathia, P. Stanislaw, and H. A. Heras, "Power-assisted adenoidectomy," Archives of Otolaryngology— Head and Neck Surgery. 1997; 123:685-688.
17. Pagella F, Pusateri A, Canzi P, Caputo M, Marseglia A, Pelizzo G, Matti E. The evolution of the adenoidectomy: analysis of different power-assisted techniques. Int J Immunopathol Pharmacol. 2011; 24:55-59.
18. Öztürk Ö, Polat Ş. Comparison of transoral power-assisted endoscopic adenoidectomy to curettage adenoidectomy. Adv Ther. 2012; 29:708-721.
19. Yılmaz M.D, Kahveci O.K, Okur E, Yucedag F. The Effect of The Adenoid Hypertrophy Rate On Upper Airway Obstruction Symptoms. KBB-Forum 2011;10(4):74-79