



## TECHNICAL WRITING

# LATERAL ALAR CAUDAL STRUT GRAFT: EFFICACY OF A NOVEL TECHNIQUE IN TIP PLASTY

Süreyya ŞENELDİR<sup>1</sup>, MD; Yasin KULAKSIZ<sup>2</sup>, MD;

<sup>1</sup>Süreyya Şeneldir Klinik, Kulak Burun Boğaz, İstanbul, Turkey <sup>2</sup>Bezmialem Vakıf Üniversitesi, Kulak Burun Boğaz, İstanbul, Turkey

### SUMMARY

**Objective:** An ideally positioned nasal tip is one of the many aspects important for an aesthetically pleasing nose. The stiffness and shape of the lateral crus are primarily responsible for the nasal tip support. In this article, the authors discuss the functional and aesthetic effect of the lateral alar caudal strut graft (LACSG) on the nasal tip.

**Material and Methods:** Included in the study were 65 patients (41 women, 24 men) undergoing rhinoplasty using LACSG with the senior author as surgeon between 2017 and 2020. The mean age was 27.6 years (range 18-45). The mean postoperative follow-up period was 22.3 months (range 12-36). Patients who completed the 1-year postoperative period completed the rhinoplasty outcome evaluation (ROE) questionnaire. Outcome measures were performed at examinations, and preoperative and postoperative photographs of the patients were analyzed.

**Results:** In the postoperative follow-up, no revision surgery was required for technique-specific reasons. We achieved the highlight called lateral alar definition in all patients with the LACSG. We saw remarkable functional and aesthetic improvements with this graft in patients with retracted alar rim and weak lateral wall and nasal tip support. According to the ROE questionnaire, 90.7% (59 out of 65) of the patients were content with the aesthetic and functional results.

**Conclusion:** The LACSG is a new variant graft for tip plasty that helps prevent alar rim retraction, strengthens the lateral nasal wall and the lateral crus, and stabilizes the tip. In addition, this graft strongly supports the lateral alar definition.

**Keywords:** Lateral crural strut graft, external nasal valve, tip plasty, rhinoplasty

### LATERAL ALAR KAUDAL DESTEK GREFTİ: TİP PLASTİDE YENİ BİR TEKNİĞİN ETKİNLİĞİ ÖZET

**Amaç:** İdeal olarak konumlandırılmış burun ucu, estetik açıdan hoş görünen bir burnun birçok yönünden biridir. Lateral krusların sertliği ve şekli, burun ucu desteğinden primer olarak sorumludur. Çalışmamız, lateral alar kaudal destek greftinin burun ucuna olan fonksiyonel ve estetik etkisini araştırmayı amaçlamıştır.

**Materyal ve metod:** Bu çalışma, 2017 ile 2020 tarihleri arasında kıdemli yazar tarafından ameliyat edilen 65 hasta (41 kadın, 24 erkek) ile oluşturulmuş retrospektif bir çalışmadır. Hastaların ortalama yaşı 27.6 yıl (18-45) idi. Ameliyat sonrası ortalama takip süresi 22.3 aydı (range 12-36). 1 yıllık postoperatif dönemi tamamlayan hastalar, rinoplasti sonuç değerlendirme (ROE) anketini doldurdu. Sonuçlar, ameliyat öncesi ve ameliyat sonrası fotoğrafların karşılaştırılmaları ve burun muayeneleri ile değerlendirildi.

**Sonuçlar:** Postoperatif takipte tekniğe özgü nedenlerden dolayı revizyon cerrahisine gerek duyulmadı. LACSG uygulanmış tüm hastalarda lateral alar vurgu adı verilen ışığa ulaştık. Alar rim retraksiyonunda ve lateral nasal duvarı ve burun ucu desteği zayıf olan hastalarda bu greft ile dikkat çekici fonksiyonel ve estetik gelişmeler gördük. ROE anketine göre hastaların %90,7'si (65 hastanın 59'u) estetik ve fonksiyonel sonuçlardan memnundu.

**Sonuç:** LACSG, alar rim retraksiyonunu önlemeye yardımcı olan, lateral nazal duvar ve lateral krusu güçlendiren ve burun ucunu stabilize eden, tip plasti için yeni bir varyant grefttir. Ek olarak, bu greft lateral alar vurguyu güçlü bir şekilde desteklemektedir.

**Anahtar Sözcükler:** Lateral krural destek grefti, eksternal nazal valve, tip plasti, rinoplasti

## INTRODUCTION

An ideally positioned nasal tip is one of the many aspects important for an aesthetically pleasing nose<sup>1</sup>. In rhinoplasty surgeries, an ideal tip is achieved by creating harmony among

Corresponding Author: Yasin KULAKSIZ MD Bezmialem Vakıf Üniversitesi, Kulak Burun Boğaz, İstanbul, Turkey, E-mail: yasink92@gmail.com

Received: 08 September 2022, revised for: 24 November 2022, accepted for publication: 13 August 2022

Cite this article: Şeneldir S., Kulaksız Y. Lateral Alar Caudal Strut Graft: Efficacy of A Novel Technique in Tip Plasty. KBB-Forum 2022;21(4):229-235

the skin, soft tissue envelope and underlying nasal skeleton<sup>2-4</sup>. The basic structures comprising the nasal skeleton include both alar cartilages, the caudal septum, and the nasal spine<sup>5</sup>. The stiffness and shape of the lateral crus are primarily responsible for the nasal tip support and the dynamic stability of the nasal valves<sup>6,7</sup>. The contribution of the lateral crus to the size, contour, projection, and rotation of the tip of the nose is often underestimated<sup>8,9</sup>.

The lateral crus is one of the most important structures supporting the alar rim and lobules. For the lateral crus to support the rim, the caudal border of the lateral crus must be close to the medial alar rim, and its caudal part must be more anterior than the cephalic part. A

robustly supported rim gives rise to symmetrical curvature and stabilizes the alar rim, and appears triangular when viewed from below<sup>7,10</sup>.

The lateral crural strut graft (LCSG) was first described by Gunter and Friedman in 1997. It was later popularized by Toriumi and Asher and continues to be used by many surgeons<sup>11</sup>. LCSG is highly effective for correcting boxy nasal tips, malpositioned lateral crus, alar rim retraction, and alar rim collapse<sup>12,13</sup>. Many LCSG grafts have been described<sup>14-17</sup>. In this paper, we introduce the LACSG, a variant of the LCSG that starts just lateral to the dome and continues along the caudal part of the lateral crus.

Here, we retrospectively examined the effects of the LACSG on tip stability, the lateral nasal wall, and alar rim integrity. In addition to aesthetic and functional outcomes, as previously defined by Tardy and Toriumi<sup>9,18</sup>, we also demonstrate a "lateral alar definition" highlight effect obtained using the LACSG graft, which can be seen in lateral photographs.

#### MATERIAL and METHODS

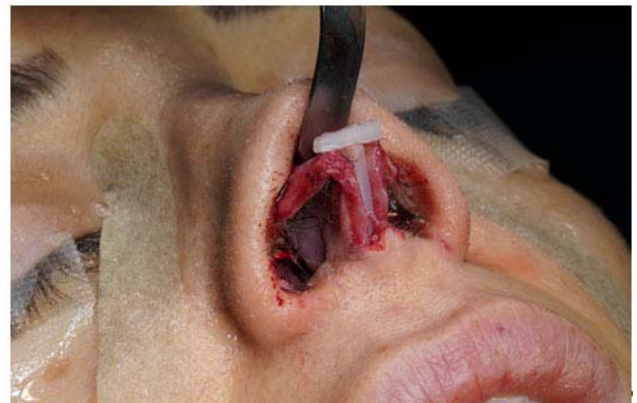This retrospective study was conducted on 65 patients treated between March 2017 and August 2020. The patients consisted of 41 (63%) women and 24 (37%) men with a mean age of 27.6 years (range: 18-45 years). Preoperative, intraoperative, and postoperative photographs and videos were routinely obtained for graft evaluation.

To determine the nasal skin thickness among patients who underwent rhinoplasty surgery, mean nasal skin thickness was obtained by Obagi skin pinch test<sup>19</sup>. It is a simple and reliable method in which thin, normal, and thick skin are evaluated for dermal thickness at a keystone junction, with averages of 0.3 mm (0.2-0.4 mm), 0.5 mm (0.3-1.1 mm), and 0.9 mm (0.6-1.2 mm), respectively.

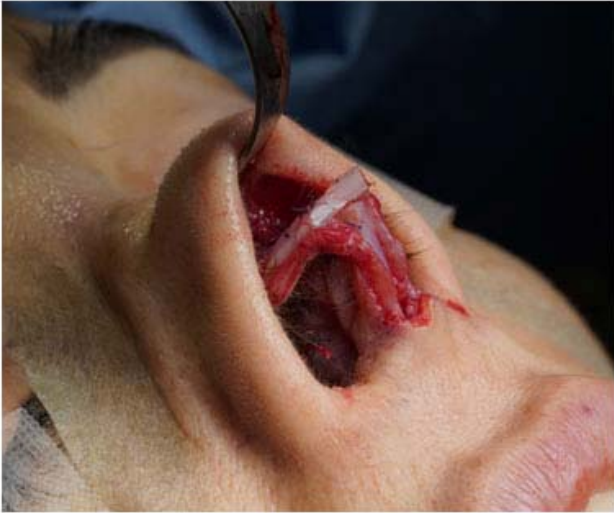All patients were administered general anesthesia. Lidocaine with epinephrine (2%) (1:200, 000) was locally administered to reduce intraoperative bleeding. Open rhinoplasty was performed with stepwise dissection. An inverted V-shaped transcolumellar incision was made, along with a bilateral marginal incision. Supraperichondrial dissection of the skin and soft tissue envelope was performed up to the rhinion. Subsequently, septoplasty was

performed after subperiosteal elevation of the nasal bones. After osteotomy and reconstruction of the middle vault, tip plasty was performed following application of horizontal mattress sutures, a columellar strut and cap grafts (Fig. 1), and the LACSG procedure was initiated. The LACSG was placed in a pocket opened with scissors in the alar lobule, starting just lateral to the cap graft and continuing caudally over the lateral crus (Fig. 2). The graft was fixed to the lateral crus with 6/0 PDS sutures from two separate sites (Video 1). The mean size of the graft was 20 mm in length, 2 mm in width, and 1 mm in height (Fig. 3). After the same procedures had been applied to both sides, as well as camouflage grafts, the incisions were sutured and the operation was successfully completed. The LACSG placement is shown schematically in Fig. 4 and the functional outcome is shown in Fig. 5.


The aesthetic and functional outcomes were evaluated separately by the patients and surgeons. Surgical outcomes were evaluated by comparison of preoperative photographs with the most recent postoperative photographs (taken at least 12 months after surgery), and via nasal examinations. All pre- and postoperative photographs were standardized and taken under the same settings, keeping the subject distance and angle constant. Postoperatively, the function and aesthetics of the entire nose, including the nasal tip and dome contours, contours of the alar rim and lobule, and lateral crura, were evaluated. In addition, the patients were asked to evaluate their rhinoplasty results through a rhinoplasty outcome evaluation (ROE)<sup>20</sup> questionnaire during an outpatient visit at least 1 year after the operation.



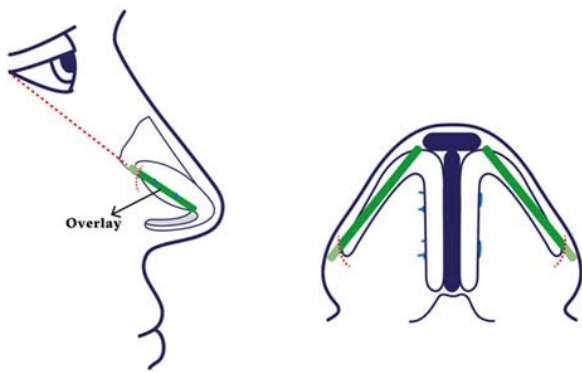
**Fig 1:** Intraoperative view of the nasal tip after application of horizontal mattress sutures, a columellar strut and cap grafts.




**Fig 2:** Intraoperative view of the nasal tip after LACSG placement.



**Fig 3:** The LACSG is 20 mm long, 2 mm wide, and 1 mm deep.



**Fig 4:** The lateral alar caudal strut graft (LACSG). The LACSG is placed in a pocket opened with scissors in the alar lobule, beginning just lateral to the cap graft and continuing over the caudal lateral crus (overlay) toward the lateral canthus.



**Fig 5:** LACSG supports the alar rim and lateral nasal wall via placement of the caudal lateral crus more anteriorly than the cephalic part. In addition, this creates a highlight effect, which we refer to as lateral alar definition.

## RESULTS

Open rhinoplasty was applied in all 65 patients (41 women, 24 men) who underwent primary rhinoplasty surgery. Only cases of rhinoplasty surgery involving LACSG performed by a senior surgeon were included in this study. The mean postoperative follow-up time was 22.3 months (range: 12-36 months). Eighteen percent of patients (n = 12) were found to have thin skin, 57% (n = 37) to have normal skin, and 25% (n = 16) thick skin.

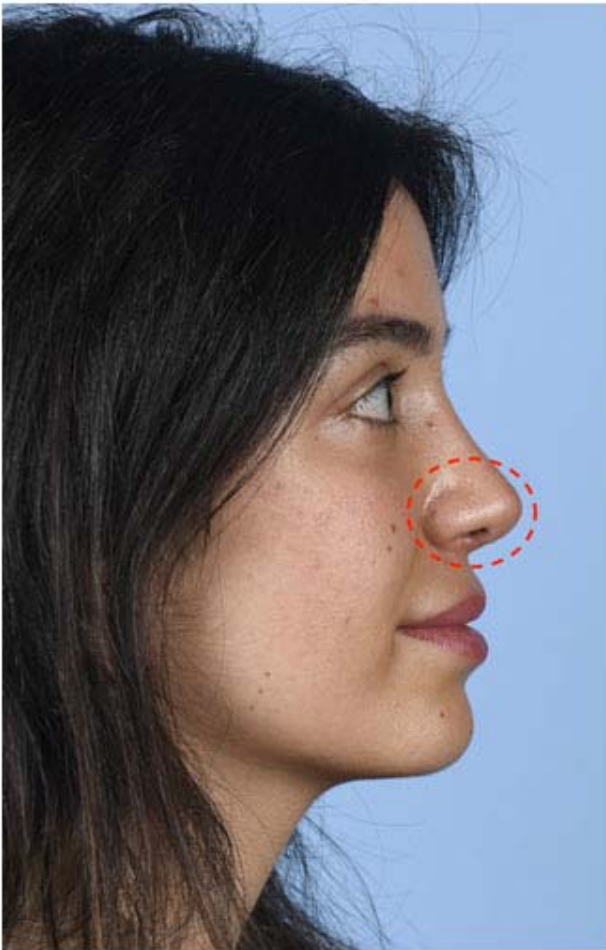We refer to this functional and aesthetic highlight as lateral alar definition, which starts just lateral to the dome and ending in the alar lobule, in photographs taken on the operating table and during postoperative controls (Figure 6). We achieved this highlight in each patient treated with the LACSG graft. This highlight effect is indicative of a strong lateral crus, well-supported alar rim, and strong lateral nasal wall; in contrast, patients with a pinched nasal tip have a weak lateral crus, retracted alar rim, or weak lateral nasal wall (Fig. 7).

Evaluations were performed by comparing postoperative photographs taken at least 1 year after the operation with presurgical photographs. Patients were also evaluated during outpatient clinical visits. During follow-up, the symmetry, projection, and rotation of the nose were checked for a natural appearance; the alar opening provided by the graft and triangular appearance were confirmed to be well-preserved when viewed from below. According to the ROE questionnaire, 59 of the 65 patients (90.7%) were satisfied with the aesthetic and functional results

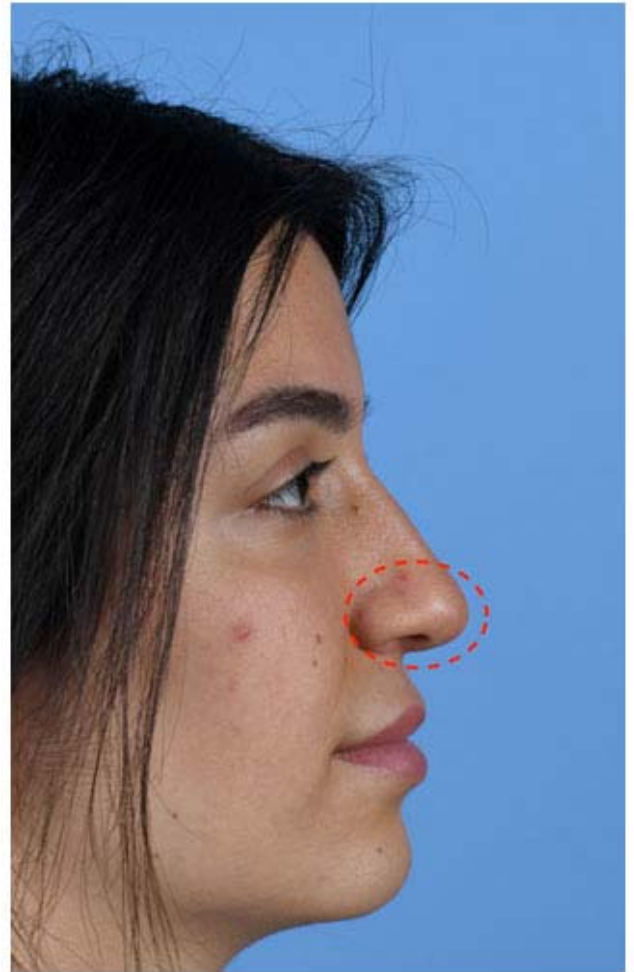


of the rhinoplasty. None of the patients required revision surgery, and there were no other complications, such as graft visibility or "tombstone deformity", over the 3-year follow-up period.

We achieved remarkable functional and aesthetic improvements with the LACSG graft in patients with weakened tip support, a weakened alar rim, or retraction. Pre- and postoperative photographs of the two patients with thin and normal skin this study are shown in Figs. 8 and 9, respectively.



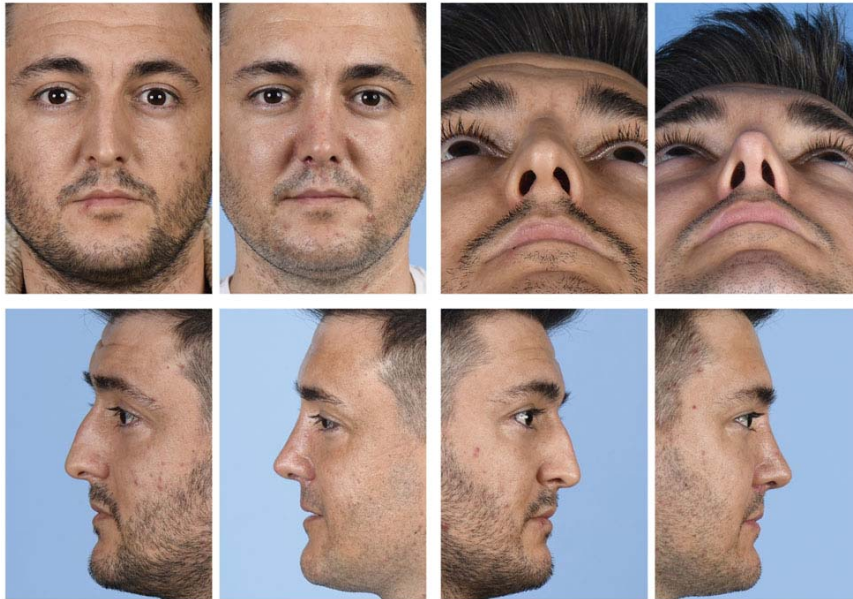**Fig 6:** Lateral alar definition (the highlight effect), as seen in lateral photographs.



**Fig 7:** Irregular light shadows in a patient with a weak lateral nasal wall.



**Fig 8:** Preoperative and postoperative images of a thin-skinned patient taken 1 year after rhinoplasty using the LACSG. The lateral alar definition highlight effect was maintained in the lateral view, and the triangular structure was well-preserved when viewed from below.



**Fig 9:** Preoperative and postoperative images of another a normal-skinned patient taken 1 year after rhinoplasty using the LACSG. The lateral alar definition was maintained in the lateral view, and the triangular structure was well-preserved when viewed from below.

## DISCUSSION

The primary aesthetic goal of rhinoplasty is to create a nose compatible with the facial contours. An aesthetically pleasing and natural-looking nose can be achieved by creating smooth transitions and achieving harmony and symmetry between light and shadow<sup>21</sup>. Many studies performed nasal surface analysis based on light reflections. Sheen divided the tip of the nose into four main compartments: the columella-lobular junction, tip point, and lateral extensions of the right and left "dome points"<sup>22</sup>. Meanwhile, Toriumi defined the ideal nasal tip based on shadows in the supratip, alar groove, and facet regions through three-dimensional analysis<sup>9</sup>. In addition to the above, in this study, we defined a highlight as a lateral alar definition, which starts just lateral to the dome and ends in the alar lobule. This highlight is indicative of a strong lateral crus, well-supported alar rim and "patent" external nasal valve. The highlight is not seen in patients with a weak lateral crus, retracted alar rim, or external nasal valve deficiency. The LACSG provided the highlight for each patient, because it was located on the lateral crus close to the alar rim and supported both the alar rim and lateral nasal wall.

LCSGs offer a versatile solution for a variety of lateral crural deformities and deficiencies. These grafts have been shown to be useful for correcting a broad nasal tip, malpositioned lateral crura, alar rim retraction, alar rim collapse, and concave lateral crus. They were first introduced by Gunter and Friedman in 1997 and later popularized by Toriumi and Asher<sup>11</sup>. Many variants of LCSG grafts have since been developed, including the modified lateral crural strut graft<sup>14</sup>, the lateral crural extension graft<sup>15</sup>, miniature LCSG<sup>16</sup>, sandwiched lateral crural reinforcement graft<sup>17</sup>, and extended alar contour grafts<sup>23</sup>. Original description and supporting cadaver studies to harvest the LCSG used an average of a 20 to 30 mm length and a width of 4 to 10 mm, which adds burden to the cartilage available for grafting<sup>12,24</sup>. On the contrary, this is not the case in the newly described LACSG, where a 20 mm × 2 mm LACSG is used along the caudal half of the lateral crus to reshape and straighten the lateral crus. In contrast to the aforementioned grafts, the LACSG graft discussed in this study is a very thin, lightweight graft placed as an overlay caudal to the lateral crus, unlike the alar rim grafts, thereby strongly supporting the lateral nasal wall and alar rim.



A pinched nasal tip may occur due to congenital weakness, malposition, concavity, or recurvature of the lateral crus. However, its most common manifestation is iatrogenic. Many of the traditional nasal tip shaping techniques are designed to narrow the tip and reduce supratip fullness, and these techniques can produce an unnatural-looking, overly narrow, compressed, and poorly supported nasal tip that appears isolated from the surrounding nasal subunits, disrupting the overall harmony and balance of the nose. To prevent pinched nasal tip deformities, the lateral crus should be located caudally, close to the alar rim, and the caudal lateral crus should be more anterior than the cephalic part. This configuration provides adequate support for the alar rim and helps prevent retraction<sup>25</sup>. Aggressive tip suturing may be required to achieve this configuration. The LACSG graft described here helps to prevent a pinched nasal tip by avoiding the need for aggressive suturing, positioning the lateral crus more caudally, bringing it closer to the alar rim, and ensuring that the caudal lateral crus is more anterior than the cephalic part.

In the frontal view, an attractive nasal tip contour has a horizontally emerging highlight at the tip, with shading in the supratip area above and soft tissue facet area below. This highlight continues from the dome point to the alar lobule, and then on to the alar rim as a continuum without shadowing or interruption. When viewed from below, an ideal nasal configuration appears triangular, without notching between the tip lobule and alar lobule<sup>9,25</sup>. In our cases, LACSG was shown to provide strong for transfer of the highlight at the dome-defining point to the alar lobule, laterally in the lateral view, and facilitated creation of a triangular appearance when viewed from below.

In rhinoplasty surgery, the ideal tip is achieved by creating harmony among the skin, soft tissue envelope and underlying nasal skeleton<sup>2-4</sup>. Many types of graft have been used to refine the tip, lengthen the infratip lobule, and increase tip projection. Tip grafts may become visible, especially in patients with thin skin, after resolution of postoperative edema. In the long-term, this may cause a complication called tombstone deformity, which occurs due to

increased visibility of the straight edges of the tip graft<sup>26</sup>. As the LACSG graft described in this study starts just lateral to the cap graft, it is well-camouflaged and helps prevent tombstone deformity, especially in patients with thin skin. There were no cases of graft visibility or tombstone deformity in our patient population.

In summary, LACSG is a straightforward and effective approach to provide support for the lateral nasal wall and increase alar harmony. The advantages of the LACSG graft are: ensuring the caudal part of the lateral crus more anterior than the cranial part, providing the alar rim support, obtaining a triangular appearance from the basal view, achieving lateral alar definition highlight effect, providing camouflage of the cap graft, avoiding too excess sutures for eversion of the caudal portion of the lateral crus and minimizing visibility due to a very lightweight and thin graft. The limitations of this technique are as follows: (1) It is necessary to use it with cap grafts. (2) If it's too thick, it can be palpable and visible. (3) If it's too thin, it won't work.

This study had some limitations: the sample size was relatively small and all surgeries were performed by a single surgeon. In addition, the senior author was not blinded to the technique, which may have led to bias. The LACSG were only applied to cases of basic technique rhinoplasty, and existing grafts should also be compared against other tip plasty techniques.

## CONCLUSION

The LACSG is a new variant graft for tip plasty that helps prevent alar rim retraction, strengthens the lateral nasal wall and the lateral crus, and stabilizes the tip. Using the LACSG, we can achieve good aesthetic and functional outcomes, and a highlight effect (lateral alar definition) in all patients. Further long-term studies with more patients are needed.

**The funding source, financial disclosures:** None

**Conflict of interest:** None

## REFERENCES

1. Afrooz, P. N., Carboy, J. A., Mendez, B. M. & Rohrich, R. J. Cephalic Rotation of the Nasal Tip. *Plast Reconstr Surg* 143, 734E-743E (2019).





2. Adams, W. P. et al. Anatomic basis and clinical implications for nasal tip support in open versus closed rhinoplasty. *Plast Reconstr Surg* 103, 255-264 (1999).
3. Dhir, K. & Ghavami, A. Reshaping of the Broad and Bulbous Nasal Tip. *Clinics in Plastic Surgery* vol. 43 115-126 Preprint at <https://doi.org/10.1016/j.cps.2015.09.013> (2016).
4. Byrd, H. S. & Hobar, P. C. Rhinoplasty: A practical guide for surgical planning. *Plast Reconstr Surg* 91, 642-654 (1993).
5. Ketcham, A. S. & Dobratz, E. J. Normal and variant anatomy of the nasal tip. *Facial Plastic Surgery* 28, 137-144 (2012).
6. Janeke, J. B. & Wright, W. K. Studies on the Support of the Nasal Tip. *Arch Otolaryngol* 93, 458-464 (1971).
7. Toriumi, D. M. Nasal Tip Contouring: Anatomic Basis for Management. *Facial Plast Surg Aesthet Med* 22, 10-24 (2020).
8. Angelos, P. C., Been, M. J. & Toriumi, D. M. Contemporary review of rhinoplasty. *Archives of Facial Plastic Surgery* vol. 14 238-247 Preprint at <https://doi.org/10.1001/archfacial.2012.577> (2012).
9. Toriumi, D. M. & Checcone, M. A. New Concepts in Nasal Tip Contouring. *Facial Plast Surg Clin North Am* 17, 55-90 (2009).
10. Davis, R. E. & Ostby, E. T. How to Create Ideal Alar Form and Function. *Facial Plastic Surgery* 36, 034-045 (2020).
11. Kondo, M., Orgain, C., Alvarado, R., Marcells, G. N. & Harvey, R. J. The effects of lateral crural tensioning with an articulated alar rim graft versus lateral crural strut graft on nasal function. *Facial Plast Surg Aesthet Med* 22, 281-285 (2020).
12. Gunter, J. P. & Friedman, R. M. Lateral crural strut graft: Technique and clinical applications in rhinoplasty. *Plast Reconstr Surg* 99, 943-955 (1997).
13. Toriumi, D. M. & Asher, S. A. Lateral crural repositioning for treatment of cephalic malposition. *Facial Plastic Surgery Clinics of North America* vol. 23 55-71 Preprint at <https://doi.org/10.1016/j.fsc.2014.09.004> (2015).
14. Pellarin, L., Santos Bosaipo, C., Suguri Magalhães, V., Lobato Gregório, L. & Gregório, L. C. Modified Lateral Crural Strut Graft for Lateral Nasal Wall Insufficiency. *Plastic and Reconstructive Surgery* vol. 145 1015e-1016e Preprint at <https://doi.org/10.1097/PRS.00000000000006763> (2020).
15. Marianetti, T. M. & Moretti, A. Correction of alar rim retraction by lateral crural extension graft. *Acta Otorhinolaryngologica Italica* 40, 211-216 (2020).
16. Abdelwahab, M. & Most, S. P. The miniature lateral crural strut graft: Efficacy of a novel technique in tip plasty. *Laryngoscope* 130, 2581-2588 (2020).
17. Kuran, I. & Öreroğlu, A. R. The sandwiched lateral crural reinforcement graft: A novel technique for lateral crus reinforcement in rhinoplasty. *Aesthet Surg J* 34, 383-393 (2014).
18. Tasman, A. J. Rhinoplasty Photography: Lighting from above Improves Visualization of Deviations and Irregularities. *Facial Plast Surg Aesthet Med* 23, 126-131 (2021).
19. Kosins AM, Obagi ZE. Managing the Difficult Soft Tissue Envelope in Facial and Rhinoplasty Surgery. *Aesthetic Surg J*. 2017;37(2):143-157. doi:10.1093/ASJ/SJW160
20. Alsarraf, R., Larrabee, W. F., Anderson, S., Murakami, C. S. & Johnson, C. M. Measuring cosmetic facial plastic surgery outcomes: a pilot study. *Archives of facial plastic surgery: official publication for the American Academy of Facial Plastic and Reconstructive Surgery, Inc. and the International Federation of Facial Plastic Surgery Societies* 3, 198-201 (2001).
21. Öztürk, A., Sözen, T., Karıcı, H. B. & Göde, S. Objective Assessment of Nose Tip Light Reflections in Rhinoplasty. *Aesthetic Plast Surg* 43, 1028-1033 (2019).
22. Daniel, R. K., Hodgson, J. & Lambros, V. S. Rhinoplasty: The light reflexes. *Plast Reconstr Surg* 85, 859-866 (1990).
23. Cochran, C. S. & Sieber, D. A. Extended alar contour grafts: An evolution of the lateral crural strut graft technique in rhinoplasty. *Plast Reconstr Surg* 140, 559E-567E (2017).
24. Silva Filho, R. D. O. & Pochat, V. D. de. Anatomical study of the lateral crural strut graft in rhinoplasty and its clinical application. *Aesthet Surg J* 36, 877-883 (2016).
25. Hyman, A. J., Khayat, S. & Toriumi, D. M. Correction of Nasal Pinching. *Facial Plastic Surgery Clinics of North America* vol. 27 477-489 Preprint at <https://doi.org/10.1016/j.fsc.2019.07.004> (2019).
26. Seneldir, S., Nacar, A. & Kayabasoglu, G. A novel method for smooth contouring of nasal tip: Camouflaging Alar tip graft. *Journal of Craniofacial Surgery* 26, 2171-2173 (2015).