



## CASE REPORT

# MALIGNANT PERIPHERAL NERVE SHEATH TUMOR PRESENTING AS A PAROTID MASS

Gül CANER, MD<sup>1</sup>; Güliz ÖZKÖK, MD<sup>2</sup>; Gül Deniz GÜLER, MD<sup>1</sup>; Erdal GÜL, MD<sup>1</sup>;  
Mehmet Ziya ÖZÜER, MD<sup>1</sup>; Hakan POSTACI, MD<sup>2</sup>

<sup>1</sup>Ministry of Health, Izmir Training and Research Hospital, Otorhinolaryngology Clinic, Izmir, Turkey

<sup>2</sup>Ministry of Health, Izmir Training and Research Hospital, Pathology Department, Izmir, Turkey

### SUMMARY

Malignant peripheral nerve sheath tumors are rare in the head and neck region. A tumor arising in the intraparotid region of the facial nerve, suggestive of pleomorphic adenoma preoperatively is presented. Facial nerve was found to be involved by tumor intraoperatively, requiring total parotidectomy and sacrifice of the involved portion of the facial nerve. Adjuvant radiotherapy was given. Possibility of an unusual tumor must be kept in mind when dealing with parotid masses, even if the preoperative studies are suggestive of a pleomorphic adenoma.

*Keywords: Malignant peripheral nerve sheath tumor, Facial nerve, Parotid*

### PAROTİS KİTLESİ ŞEKLİNDE BULGU VEREN MALİGN PERİFERİK SİNİR KILIFI TÜMÖRÜ

#### ÖZET

Malign periferik sinir kılıfı tümörlerine baş-boyun bölgesinde ender olarak rastlanır. Operasyon öncesinde parotis bezi kökenli pleomorfik adenomu düşündüren, ancak intraparotid fasiyal sinirden kaynaklanan malign periferik sinir kılıfı tümörü olgusu sunulmaktadır. Operasyon sırasında fasiyal sinirin invaze olduğu saptanmış ve total parotidektomiyle birlikte fasiyal sinirin invaze parçası eksize edilmiştir. Adjuvan radyoterapi uygulanmıştır. Parotis kitlelerine yaklaşımda, preoperatif incelemeler pleomorfik adenomu düşündürse bile nadir karşılaşılan tümörlerin de ayırıcı tanıda akılda bulundurulması gerekmektedir.

*Anahtar Sözcükler: Malign periferik sinir kılıfı tümörü, fasiyal sinir, parotis kitlesi*

### INTRODUCTION

Malignant peripheral nerve sheath tumors (MPNSTs) are malignant tumors developing from cells present in the peripheral nerve tissue<sup>1</sup>, the estimated incidence of MPNST being 0.001%. These tumors are generally associated with neurofibromatosis and previous irradiation<sup>2,3</sup>.

### CASE PRESENTATION

A 64 year-old man presented with a three month history of slowly growing mass in his face. Physical examination revealed a semi-mobile mass of approximately 5 cm in diameter in the right parotid region. There was no history of facial weakness. Preoperative computerized tomography showed a 4.3x4.1 cm mass with relatively unclear margins in the superficial part of the gland and was interpreted as a possible pleomorphic adenoma (Figure 1). System examinations and chest x-ray were normal. A superficial parotidectomy was planned.

However, invasion of surrounding parotid tissue and involvement of the facial nerve were encountered intraoperatively.

The surgeon was unable to isolate the facial nerve from tumor. A total parotidectomy was performed, sacrificing the involved portion of the facial nerve. Marginal mandibular, cervical and part of the temporal branches were free of disease. Histological examination revealed that tumor was hypercellular throughout and showed fascicular and whorled growth pattern (Figure 2). The tumor cells were spindle and plump, but in some areas the cells were wavy. Normal nerve tissue sections surrounded by tumor tissue were observed (Figure 3). Nuclei were hyperchromatic and pleomorphic. Mitotic figures were more than 5 per 10 HPF (high power field). Areas of compressed parotid tissue in the periphery of tumor was observed. Immunohistochemically tumor cells were positive for S100 and vimentin, but negative for EMA (epithelial membrane antigen), actin and cytokeratin. The histological diagnosis was low-grade MPNST.

Postoperatively the patient had complete facial paralysis (Grade VI, House-Brackmann). Distant metastasis was ruled out by cranium, abdomen and thorax CT scans, after which local

Corresponding Author: Gül Caner MD; Ministry of Health, Izmir Training and Research Hospital, Otorhinolaryngology Clinic, Izmir, Turkey, E-mail: gulc@isbank.net.tr

Received: 16 April 2006, revised for: 27 Jun 2006, accepted for publication: 09 August 2006

radiotherapy (60Gy) was given, mainly to the tumor excision site and the surrounding area.

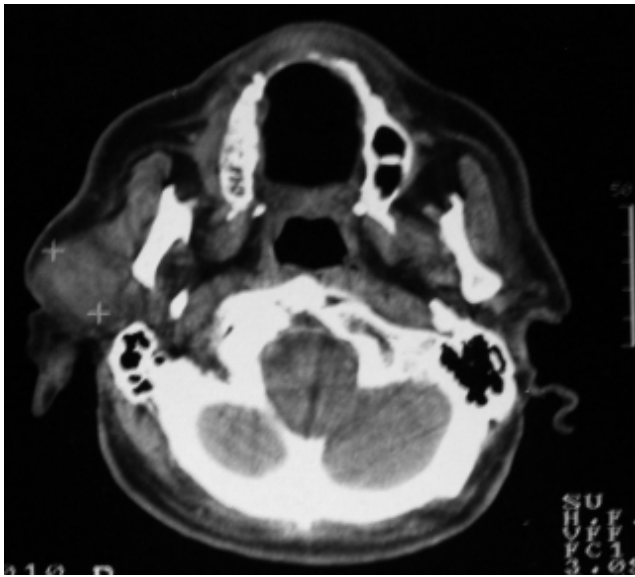


Figure 1. Preoperative CT scan showing a right parotid mass

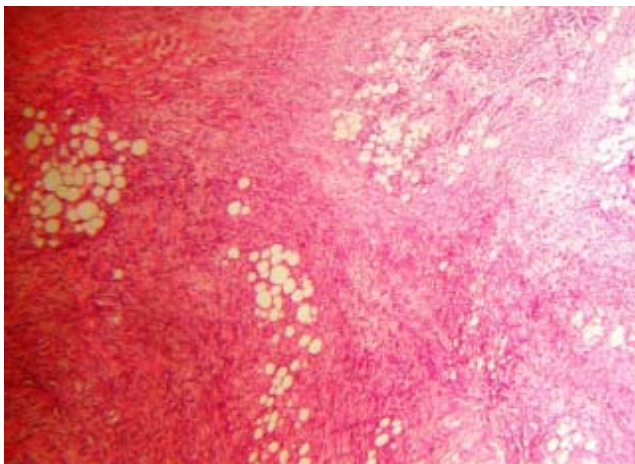


Figure 2: Parotid tissue and fascicular growth pattern of tumor

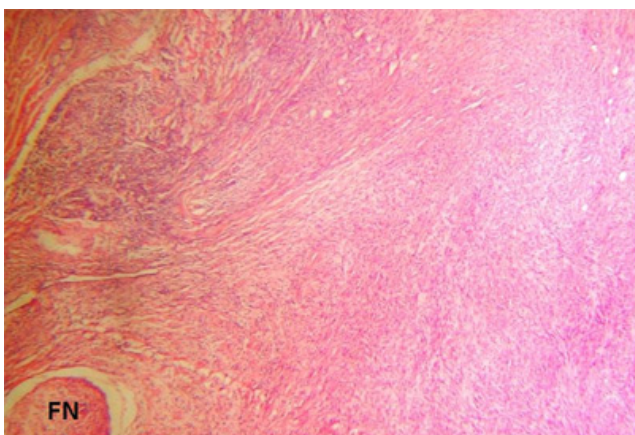


Figure 3. Facial nerve and tumor tissue, FN= Facial Nerve

Patient underwent facial rehabilitation and facial functions progressed to Grade III at postoperative 8th month. 13 months postoperatively, he developed a spontaneous fracture at the right

mandibular condyle with simultaneous worsening of facial paralysis. Maxillofacial surgery consultation revealed the reason to be radionecrosis at mandibular bone and no surgical intervention but conservative treatment was recommended, because of risk of local complications. The patient is currently free of disease 18 months postoperatively but he has still facial paralysis.

## DISCUSSION

More than 75% of parotid tumors are benign. Because of the unsightly appearance of parotid masses, the potential for malignancy, and the relative ease of resection via superficial parotidectomy, excisional biopsy is the most common method of treatment. Facial nerve dysfunction, adherence to the surrounding tissue, or cervical lymphadenopathy on physical examination suggests malignancy, and in this setting preoperative imaging and fine needle aspiration biopsy are more frequently used<sup>4</sup>.

Preoperatively, it is not simple to differentiate a MPNST from other benign or malignant parotid tumors. Also there has been no definitive finding for intraparotid lesions. Fine needle biopsy has not been shown to be a diagnostic modality for benign or malignant nerve sheath tumors<sup>5</sup>.

MPNST arises from or shows differentiation toward peripheral nerve sheath cells. These tumors affect primarily the 20-50 year old age group, and about half develop in patients with neurofibromatosis—type 1 (NF-1). MPNST arise primarily in the extremities or the trunk. Cranial nerves are uncommonly involved. There is a wide histologic spectrum. The most common is that of a highly cellular, spindle cell tumor with a variable degree of nuclear pleomorphism. Immunophenotyping shows focal staining for S-100 and CD57. Some 2 to 15 percent of patients with neurofibromatosis may develop a malignant transformation in one of their tumors, chiefly those deep in the neck or extremities. Superficial lesions rarely become malignant<sup>6</sup>.

The estimated incidence of MPNST is 0.001%, but represents 5-15% of soft tissue sarcomas in the head and neck region<sup>2</sup>. They are associated with an extremely poor prognosis. Local recurrence is observed in 54% of cases, distant metastases to the lungs and bone in 65% of cases, and the five year survival rate is 34%. The age of onset tends to be lower in cases associated with NF-1<sup>7</sup>. Poor prognostic indicators are a lesion greater than 5 cm diameter, incompleteness of excision and association with neurofibromatosis<sup>1</sup>. Some authors believe that



prognosis depends on histologic findings such as cellularity, pleomorphism and mitotic activity and to the size of the tumor<sup>8</sup>. MPNST's infiltrate local tissue extensively and spread periferentially. Regional lymph node involvement is less than 1% of deep located disease.

Surgery is the choice of treatment for MPNST, requiring radical resection. Frozen section must ensure clear margins<sup>1</sup>, although reviews do not suggest a margin of excision. Since lymph node involvement is very unusual, elective neck dissection is not recommended. Adjuvant high-dose radiotherapy is used. Chemotherapy remains controversial<sup>9</sup>. Five year survival of all patients with MPNST's of the head and neck, ranges from 15-34%<sup>2</sup> with 50% of cases developing local recurrences and 33% metastasise, particularly the lung<sup>10</sup>.

Invasion of the facial nerve and parotid tissue was suggestive of a malignant parotid tumor in our case. Therefore, a total parotidectomy including the involved portion of the facial nerve was performed. The uninvolved branches of the nerve were preserved. This was probably helpful in amelioration of facial functions in the postoperative period. Facial nerve is anatomically positioned adjacent to the condylar neck of the mandible. The reason for recurrence of facial paralysis after mandibular fracture may be explained by close proximity of the nerve to condylar neck of the mandible and luxation of the condyle off the glenoid fossa. While only conservative but not surgical treatment was recommended by maxillofacial surgeon, an ongoing local pressure on facial nerve caused by mandible fragments is considered to be the reason for paralysis.

Radical resection and absence of neurofibromatosis might be the reason to relatively better course of disease in our case.

## CONCLUSION

The surgeon must keep in mind that an unusual tumor can be encountered when dealing with a parotid mass. MPNSTs arising as parotid tumors are rare. They should be resected as widely as possible and elective neck dissection is not recommended. Adjuvant radiotherapy should be given. We believe that facial rehabilitation surgery must be delayed, since recurrence rate is high.

## REFERENCES

1. Enzinger FM WS: Soft tissue tumors, ed 2. St Louis: CV Mosby, 1988
2. Hujala K, Martikainen P, Minn H, Grenman R. Malignant nerve sheath tumours of the head and neck: four case studies and review of the literature. *Eur Arch Otorhinolaryngol* 1993; 250: 379-82.

3. Ducatman BS, Scheithauer BW, Piepgras DG, Reiman HM, Ilstrup DM. Malignant peripheral nerve sheath tumors: A clinicopathologic study of 120 cases. *Cancer* 1986;57:2006-21.
4. Caughey RJ, May M, Schaitkin BM. Intraparotid facial nerve schwannoma: Diagnosis and management. *Otolaryngol Head Neck Surg* 2004;130:586-92.
5. Barnes L, Peel RL, Verbin RS. Tumors of the nervous system. In: Barnes L, editor. *Surgical pathology of the head and neck*. New York: Marcel Dekker, 1985: 662-3.
6. Weiss SW, Goldblum JR. *Enzinger and Weiss's Soft Tissue Tumors*. St Louis: Mosby Inc, 2001
7. Hruban RH, Shiu MH, Senie RT: Malignant peripheral nerve sheath tumors of the buttock and lower extremity; A study of 43 cases. *Cancer* 1990; 66: 1253-65.
8. Colreavy MP, Lacy PD, Hughes J, Bouchier-Hayes D, Brennan P, O'Dwyer AJ, Donnelly Mj, Gaffney R, Maguire A, O'Dwyer TP, Timon CV, Walsh MA: Head and neck schwannomas-a 10 year review. *J Laryngol Otol* 2000; 114: 119-24.
9. Storm FK, Eilber FR, Mirra J, Morton DL. Neurofibrosarcoma. *Cancer* 1980; 45:126-9.
10. Punjabi AP, Haug RH, Chung-Park MJ, Likavek M. Malignant peripheral nerve sheath tumor of the parotid gland: report of case. *J Oral Maxillofac Surg* 1996; 54: 765-9.