



RESEARCH

TUBERCULOUS PAROTITIS: CAN BE LEFT SILENT FOR A LONG TIME?

Adin SELÇUK, MD¹; Vedat ORUK, MD¹; Hüseyin DERE, MD¹; Fatih BOZTEPE, MD¹;
Selda SEÇKİN, MD²

¹Ankara Numune Training and Research Hospital, 4th Otorhinolaryngology Clinic, Ankara, Turkey

²Ankara Numune Training and Research Hospital, Clinic of Patology, Ankara, Turkey

SUMMARY

Tuberculous infection of the parotid gland is rare. A fifty-one-year-old woman presented with a history of 30 year swelling in preauricular region and a gradual increase in dimension at last year. Patient was suggested as parotid malignancy and underwent parotidectomy and mass excision. Pathological examination revealed a granulomatous infection. She was diagnosed as tuberculous parotitis by chest specialists and treated by anti-tuberculous-chemotherapy. Tuberculosis should be considered as part of the differential diagnosis of parotid masses.

Keywords: Parotid gland, tuberculosis

PAROTİS TÜBERKÜLOZU: UZUN SÜRE SESSİZ KALABİLİR Mİ?

ÖZET

Parotis bezinin tüberküloz enfeksiyonu nadir görülür. Ellibir yaşında bayan hasta preauriküler bölgede 30 yıllık şişlik ve son bir yılda bu şişlikte artma öyküsü ile bize başvurdu. Hasta parotis malin tümörü düşünülerek parotidektomi ve kitle eksizyonu uygulandı. Patolojik inceleme granülatöz enfeksiyon şeklinde rapor edildi. Göğüs Hastalıkları kliniğine konsulte edilerek parotis tüberkülozu tanısı ile anti-tüberküloz tedavi başlandı. Tüberküloz enfeksiyonu, parotis kitlelerinin ayırıcı tanısında akla getirilmesi gereken bir durumdur.

Anahtar Sözcükler: Parotis bezi, tüberküloz

INTRODUCTION

Infections of parotid gland is common, tuberculosis of the parotid gland however is rare even in countries where the disease is endemic such as Africa and India. Tuberculous parotitis was first described in 1981 by Kuruvilla¹. Tuberculous parotitis with pulmonary infections is seen more commonly, but primary type of isolated tuberculous parotitis is seen rarely².

The disease involves the parenchyma of the gland, either through hematogenous spread or from infection of the lymph nodes secondary to a tonsillary or a dental infection within or around the parotid gland^{3,4}. According to its ethiopathologic involvement route, the disease may present either as a result from infection of intracapsular or periglandular lymph nodes or as a diffuse gland growth because of parenchymatous tuberculosis³. Clinically it is presented as usually unilateral, slow growing parotid mass indistinguishable from a tumour.

In this case report, an interesting case of parotid tuberculosis simulating parotid neoplasm is presented.

CASE REPORT

A 51 year-old woman admitted to our department with swelling in her right preauricular region which was present for 30 year. She had also 1-year history of same-sided infraauricular swelling. The mass wasn't painful. Neither had she complaints of night sweats, nor weight loss. There was history of hypertension and diabetes mellitus for 15 years. She gave no personal or family history of tuberculosis.

In clinical examination, there was a soft, semi mobile, non-tender, circumscribed mass of 3x3x4 cm in size in the right preauricular area, which was non-fluctuant and non-erythematous. In addition to this mass, a 3x3x2 cm non-fluctuant swelling and a mass of 1 cm in diameter in the infraauricular region were detected. Both were smooth, firm and mobile. Intraoral examination was normal. No lymph nodes were palpable in the neck. Facial nerve functions were normal.

In laboratory investigation, white cell count was $10,9 \times 10^9$ /L. Erythrocyte sedimentation rate was 35mm/h. Biochemical investigations and two sided chest x-ray were normal. Thorax computed tomography (CT) was normal except pre-tracheal and precarinal lymphadenopathies. Body temperature ranged between 36.2 and 37.5 C. Skin tuberculin test (Mantoux test) was positive with a weal of 17 mm, but since BCG was positive, skin tuberculin test was

Corresponding Author: Adin Selçuk MD; Ankara Numune Eğitim ve Araştırma Hastanesi, 4. KBB Kliniği, Ankara, Türkiye, Telephone: 0 312 213 8356 E-mail: sadin27@yahoo.com

Received: 18 October 2005, revised for: 23 November 2005, accepted for publication: 27 January 2006



not found valuable. Triple repeated sputum specimen and gastric washing material showed no acid and alcohol resistant bacteria (AARB) staining. CT of the parotid and neck region showed a parotid mass of varying density and such nonhomogenous lesion with cystic areas of lower attenuation and two benign appearing masses that are not cavitated inferior to this lesion (Figure-1). Fine needle aspiration biopsy (FNAB) of the mass was negative for malignancy and granulomatous infection findings. No bacterial culture was carried out; since there was no abscess formation.

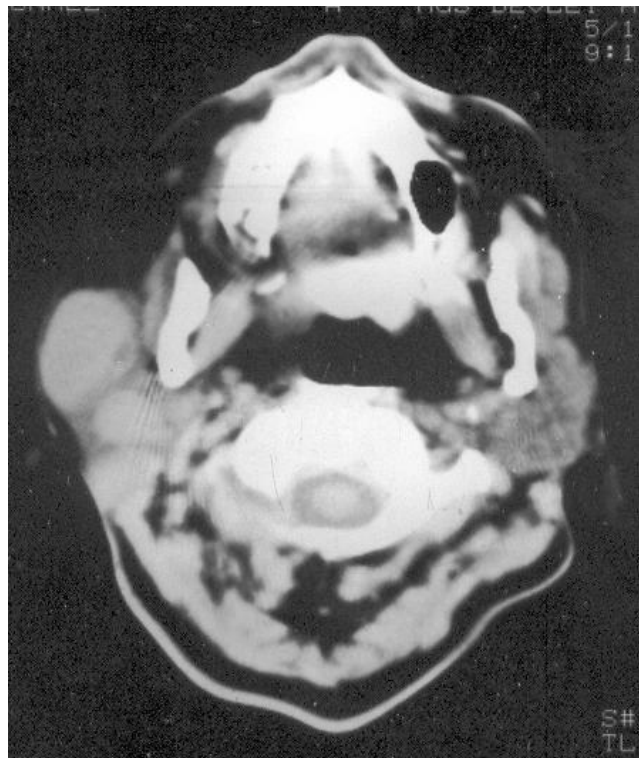


Figure 1. Computerized tomography of the parotid and neck region showing a parotid mass of varying density and such nonhomogenous lesion with cystic areas of lower attenuation and two benign appearing masses that are not cavitated inferior to this lesion

A superficial parotidectomy and mass excision was performed with preservation of the facial nerve. There was an encapsulated cystic lesion that was very closely linked to the branches of the facial nerve. Lesion was 3x4 cm in diameter in the superficial parotid region and two well-circumscribed firm and semi-mobile, 3x2 cm and 1x1 cm in diameters, masses inferior to that cystic lesion were also found and excised. In the postoperative course wound healing was well enough but grade III peripheral facial paralysis according to House-Brackman classification was developed. Since the mass was so close to the branches of the facial nerve, facial paralysis was thought to be developed due to infection. On histological examination granulomas composed of epithelial histocytes and rare langhans

type giant cells were detected, some of the granulomas had central necrosis (Figure-2). Granulomas were located in lymphoid tissue, neighbouring parotid gland and separated by thin fibrous capsule (Figure-3).

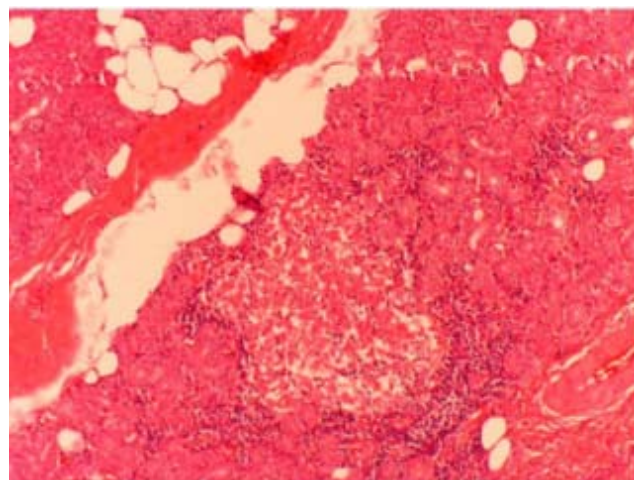


Figure-2. Granulomas composed of epitheloid histocytes with central necrosis (X40, HE)

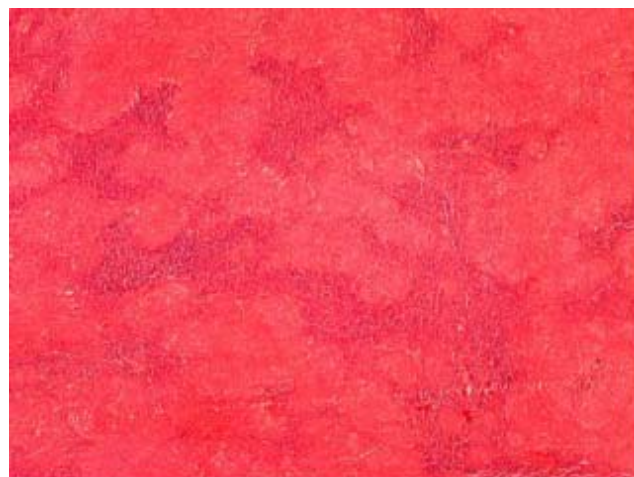


Figure-3. Granulomatous infection of the lymph node, neighbouring parotid gland (X40, HE)

Patient was evaluated by chest specialists and diagnosed as tuberculous parotid. The patient was referred to receive combined anti-tuberculosis chemotherapy and her treatment protocol was arranged as ethambutol, isoniasid, rifampicin and pyrazinamide for six months and then isoniasid and rifampicin for an additional four months. After the beginning of treatment, patient's facial nerve functions returned to normal almost completely at postoperatively second month and got well completely at sixth month.

DISCUSSION & RESULTS

Although recent studies have shown that extra pulmonary tuberculosis is not uncommon, tuberculosis parotitis is still rare^{1,4}). Patients usually present with diffuse, unilateral swelling of parotid gland of a long duration. Most of the related cases



presented with slow growing masses increasing in size gradually during 2 to 6 months, and 1 case during a 10 years period^{5,6}. Most cases were misdiagnosed as parotid tumours, with the diagnosis of mycobacterial infection only after parotidectomy and histopathologic examination⁷.

In this case, there is a history of 30 year swelling and gradually increase in dimension at last year. This increase in dimension had been considered as a carcinoma that had been developed secondary to a parotid adenoma. Together with different natures of the masses in palpation, although fine needle aspiration biopsy result was thought as granulomatous infection, these findings suggested us to surgical intervention.

FNAB; when used for the diagnosis of tuberculosis lesions has a sensitivity of 80% and has a specificity of 93%⁸. Since it is not pathognomonic in differentiating diagnosis of other granulomatous diseases and can be leading false positive results, no anti-tuberculosis chemotherapy is suggested in all time and surgical intervention is suggested especially malignancy is expected. FNAB causes false positive results especially in large and necrotic parotid neoplasms⁹.

Tuberculous parotitis can be classified into a 'focal form' that spreads from a tuberculosis infection of the intraglandular or periglandular lymph nodes, and a 'diffuse form' in which the parenchyma is involved diffusely⁴. The salivary gland register (1965-1981) contains only 2 cases of paranchymatous tuberculosis of the parotid gland. But contains 46 cases of intraglandular or periglandular lymph node involvement¹⁰. In this case parotid tuberculosis is of a focal form.

In this case, due to history of the patient, we considered, the mass was a carcinoma that was developed secondary to a parotid adenoma. 30-year history of swelling is considered as a very long duration for granulomatous infections of the gland. Clinical evaluation, negative thorax CT findings and negative AARB staining of sputum and gastric washing materials also supported our surgical decision in spite of FNAB result.

As a conclusion; tuberculous parotitis should be considered as part of the differential diagnosis of salivary gland masses. FNAB and Thorax CT are contributory to diagnosis. However, surgery is indicated for cases of malignancy suspicion.

REFERENCES

1. Kuruvilla A, Saha NK, Barton RPE, Zardawi IM. Tuberculosis of the intraparotid lymph nodes. J Laryngol Otol. 1981; 95(11): 1165-7. (PMID: 7299266)

2. Ustuner TE, Sensoz O, Kocer U. Primary tuberculosis of the parotid gland. Plastic and Recons Surg. 1991 Nov; 88(5): 884-5. (PMID: 1924579)
3. Fabian RL. Salivary glands. In: Moris PF, Malt RA, ed. Oxford Textbook of Surgery. Vol 2. Oxford: Oxford Medical Publications. 1994; 2220-6.
4. Rowe-Jones JM, Vowles R, Leighton SE, Freedman AR. Diffuse tuberculosis parotitis. The J Laryngol Otol. December 1992; Vol.106: 1094-5. (PMID: 1487671)
5. O'Connell J, George MK, Speculand B, Pahor AL. Mycobacterial infection of the parotid gland: An unusual cause of parotid swelling. J Laryngol Otol. 1993; 107: 561-4. (PMID: 8345308)
6. Bhat NA, Stansbie JM. Tuberculous parotitis: A case report. J Laryngol Otol. 1996; 110: 976-7. (PMID: 8977866)
7. Suoglu V, Erdamar B, Colhan I, Katircioglu OS, Cevikbas U. Tuberculosis of the parotid gland. J Laryngol Otol. 1998; 112: 588-91. (PMID: 9764307)
8. Weiner GM, Pahor AL. Tuberculous parotitis: Limiting the role of surgery. J Laryngol Otol. Jan 1996; Vol 110: 96-97. (PMID: 8745795)
9. Bhargava AK, Shenoy AM, Kumar RV, Nanjundappa, Rao CR. Parotid tuberculosis simulating malignancy. J Laryngol Otol. Oct 1999; Vol 113: 951-2. (PMID: 10664720)
10. Holmes S, Gleeson MJ, Cawson RA. Mycobacterial disease of the parotid gland. Oral Surg Oral Med Oral Pathol Radiol Endod. Sep 2000; 90(3): 292-8. (PMID: 10982949)