



RESEARCH

THE SIGNIFICANCE OF HISTOPATHOLOGIC TONSILLAR ACTINOMYCOSIS IN PEDIATRIC PATIENTS WITH RECURRENT ACUTE TONSILLITIS

Hasan YASAN, MD¹; Metin ÇİRİŞ, MD²; Bülent Ferdi ÖZEL, MD¹; Harun DOĞRU, MD¹; Özden ÇANDIR, MD²

¹Süleyman Demirel University Faculty of Medicine, Department of Otorhinolaryngology, Isparta, Turkey

²Süleyman Demirel University Faculty of Medicine, Department of Patology, Isparta, Turkey

SUMMARY

Background: The aim of this study is to determine the possible role of *Actinomyces* histopathologically found in tonsillar tissue on hypertrophy, fibrosis, and asymmetry of tonsils in patients with recurrent acute tonsillitis. **Materials and Methods:** One hundred and fifty consecutive patients underwent tonsillectomy with the diagnosis of recurrent acute tonsillitis were enrolled in this study. Tonsillectomy specimens stained with haematoxylin-eosin were all evaluated with light microscopy for the presence of *Actinomyces*. Patients with tonsillar specimens showing *Actinomyces* were involved in the study group and those without any findings of *Actinomyces* were involved in the control group. Two groups of patients were compared with respect to the concomitant adenoid hyperplasia, season of operation, age, gender, duration of disease, the degree of tonsillar hypertrophy and tonsillar asymmetry and fibrosis. Data were analyzed by SPSS statistics package. The Chi-squared and ANOVA tests were performed. **Results:** One hundred and fifty consecutive patients with a mean age of 8.38 ± 3.74 years (ranging from 3 to 16) were enrolled in this study. *Actinomyces* were determined in 53 (35,3 %) patients. Patients operated on during summer season, and having longer periods of complaints before surgery, female gender and older mean age had significantly more frequent *Actinomyces* in their tonsillar tissues (chi-square test: $P < .05$). The other parameters were not different between two groups. **Conclusions:** In contrary to some other studies the presence of *Actinomyces* in tonsillar tissue is an incidental finding. It is the colonization of tonsils by *Actinomyces* which does not have any clinical importance.

Keywords: *Actinomycosis, fibrosis, tonsil, tonsillectomy, tonsillitis, hypertrophy*

TEKRARLAYAN AKUT TONSİLLİTLİ ÇOCUK HASTALARDA HİSTOPATOLOJİK TONSİL AKTİNOMİKOZUNUN ÖNEMİ

ÖZET

Amaç: Bu çalışmanın amacı tekrarlayan akut tonsillitli hastaların tonsil dokularında histopatolojik olarak bulunabilen aktinomikozun, tonsil asimetrisi, fibrosis, hipertrofisi üzerine olası etkilerini araştırmaktır. **Gereç ve Yöntemler:** Bu çalışmaya tekrarlayan akut tonsillit tanısı ile tonsillektomi uygulanan ardışık 150 hasta dahil edildi. Tonsillektomi ile alınan dokular hematoksilin-eozin ile boyandıktan sonra ışık mikroskobu ile aktinomikoz varlığı bakımından değerlendirildi. Tonsil dokusunda aktinomikoz tespit edilen olgular çalışma grubunu oluştururken, aktinomikoz olmayanlar kontrol grubuna alındı. Eşlik eden adenoid hiperplazi, operasyonun yapıldığı mevsim, yaş, cinsiyet, hastalık süresi, tonsil hipertrofi derecesi, tonsil asimetrisi ve firozisi bakımından iki grup karşılaştırıldı. Veriler SPSS istatistik programında değerlendirildi. Ki-kare ve ANOVA testleri uygulandı. **Bulgular:** Bu çalışmaya, yaş ortalaması 8.38 ± 3.74 yıl, yaş dağılımı 3-16 yıl olan ardışık 150 hasta dahil edildi. Yaz mevsiminde ameliyat edilen, ameliyat öncesi şikayetleri daha uzun süreli olan, cinsiyeti bayan olan ve yaşları daha büyük olan olgularda tonsil aktinomikozu görülme sıklığı anlamlı derecede fazla idi ($P < .05$). İki grup arasında diğer parametreler bakımından anlamlı bir fark yoktu. **Sonuç:** Literatürdeki bazı çalışmaların aksine tonsil dokusunda histolojik olarak görülen aktinomikoz normal bir bulgudur. Bu durum klinik anlamı olmayan ve tonsillerin *Actinomyces* tarafından kolonizasyonu olarak tanımlanabilir.

Anahtar Sözcükler: *Aktinomikoz, fibrosis, tonsil, tonsillektomi, tonsillit, hipertrofi*

INTRODUCTION

Actinomyces are anaerobic, gram positive, non-acid fast, branched, filamentous bacteria. They colonize in gingival crypts, dental calculi and tonsillar crypts.^{1,2}

Corresponding Author: Hasan yasan MD; Süleyman Demirel Üniversitesi Tıp Fakültesi, KBB Anabilim Dalı, Isparta, Türkiye, E-mail: hayasan2003@yahoo.com

Received: 02 August 2005, revised for: 18 September 2005, accepted for publication: 30 November 2005

07-09 Ekim 2004 tarihinde Ankara'da düzenlenen Otorinolaringoloji 2004 "Güncel Yenilikler" kongresinde poster olarak sunulmuştur.

The presence of *Actinomyces* in tonsils is not synonymous with clinical fulminant disease, although it is mostly referred as tonsillar actinomycosis.¹

The relationship between actinomycosis and adenotonsillar disease has been investigated in some studies. However, results were not consistent because of methodology of these studies.^{1,3} The aim of this study was to investigate possible role of *Actinomyces* found in histopathologic section of tonsillar tissue of patients with the diagnosis of recurrent acute tonsillitis (RAT).



MATERIAL and METHODS

One hundred and fifty consecutive patients underwent tonsillectomy with the diagnosis of RAT were enrolled in this prospective study. Patients with the diagnosis of other than RAT such as; chronic adenotonsillar hypertrophy without a history of RAT, peritonsillar abscess, known craniofacial anomaly, suspicion of tumor were not included in this study. The indications of tonsillectomy due to RAT were according to one of the following criteria; 1) Seven or more acute tonsillitis attacks in the preceding year, 2) Five or more acute tonsillitis attacks in the 2 preceding years, 3) Three or more acute tonsillitis attacks in the (at least) 3 preceding years.⁴ All the patients were operated on under general anesthesia. The operation technique was dissection following cold knife incision. During operation tonsillar measurements were obtained in order to get hypertrophy grading for each tonsil. The size of each tonsil was recorded according to classification of Brodsky et al.,⁵: Grade 0; Tonsils are entirely within the tonsillar fossa. Grade 1; Tonsils occupy less than 25 % of the lateral dimension of the oropharynx as measured between anterior tonsillar pillars at mid-tonsil level. Grade 2; Tonsils occupy 25-50 % of the lateral dimension of the oropharynx as measured between anterior tonsillar pillars at mid-tonsil level. Grade 3; Tonsils occupy 50-75 % of the lateral dimension of the oropharynx as measured between anterior tonsillar pillars at mid-tonsil level. Grade 4; Tonsils occupy more than 75 % of the lateral dimension of the oropharynx as measured between anterior tonsillar pillars at mid-tonsil level. Concomitant adenoid hyperplasia, season of operation, age, gender, duration of disease, the degree of tonsillar hypertrophy and tonsillar fibrosis were all recorded.

All surgically removed tonsils were fixed in formalin, embedded in paraffin and finally prepared serial microscopic slides were stained with

haematoxylin-eosin. All microscopic slides were evaluated under light microscopy (Nikon Optiphod-B) by two pathologists unfamiliar with clinical findings of patients other than surgical diagnosis of RAT. Actinomycosis was recognized as aggregates of filamentous basophilic microorganisms arranged in a radial spoke-like fashion (Figure 1).⁶ Patients with tonsillar specimens containing actinomycotic focus or foci were included in study group, and patients with no focus of actinomycosis were included in control group. Both tonsils of the same patient were evaluated separately when comparing the fibrosis within the tissue and hypertrophy grading scale of tonsils. However, both tonsils of the same patient were evaluated as one in case of comparison of parameters such as concomitant adenoid hyperplasia, season of operation, age, gender, duration of disease. Comparison between study and control group was based on these criteria. Data were recorded in Microsoft Excel database. All analyses were performed using SPSS 10.0 for Windows (SPSS., Chicago, IL). Chi-squared test was applied to find out the statistical significance of the association between various factors and the presence of the actinomycosis. One-way ANOVA and spearman's rank-order correlation were used for analysis of tonsillar hypertrophy grading between two groups. P values less than .05 was accepted as significant.

RESULTS

One hundred and fifty consecutive patients were undergone to tonsillectomy with the diagnosis of RAT. Of the 150 patients with RAT, 79 were male and 71 were female. Patients' age were between 3 and 16 years (mean age was 8.38 ± 3.74 years). Fifty three (35.3 %) patients with actinomycosis in their tonsillar tissue were included in study group and 97 patients (64.7 %) without actinomycosis in their tonsillar tissue specimens were included in control group.

	Actinomycosis (+) (n=53)	Control group (-) (n=97)	P
Gender (Male/Female)	24 / 29	55 / 42	.03*
Mean age (years)	9.33 ± 3.16	7.85 ± 3.94	.004*
Age range (min.- max.)	3 / 16	3 / 16	-
Duration of RAT complaints (years)	4.75 ± 1.69	3.25 ± 1.58	.001*
Concomitant adenoid hyperplasia	20 (37.7 %)	41 (42.3 %)	.624
Tonsillar asymmetry	9 (16.98 %)	23 (23.71 %)	.339
Seasons			
Spring	7 (13.2 %)	34 (35.1 %)	.001*
Summer	33 (62.2 %)	19 (19.6 %)	.03*
Autumn	5 (9.5 %)	9 (9.2 %)	.28
Winter	8 (15.1 %)	35 (36.1 %)	.001*

* Statistically significant.

Table 1. Patients demographics and several factors between two groups.



	Actinomycosis (+) (n=106)	Control group (-) (n=194)	P
Mean tonsillar hypertrophy grading	1.77 ± 1.20	1.72 ± 1.17	.798
Fibrosis of tonsillar tissue	19 (17.2 %)	30 (15.5 %)	.810

*Statistically significant.

Table 2. Evaluation of each tonsillar actinomycosis regarding tonsillar hypertrophy and fibrosis.

The mean age of study group patients (9.33 ± 3.16) was significantly older from those of control group (7.85 ± 3.94) ($p = .004$). Of the 53 patients with actinomycosis, 24 were male and 29 were female. Of the 97 patients without actinomycosis, 55 were male and 42 were female. There is statistically significant gender difference between two groups ($p = .03$). Patients operated on during summer session and with longer duration of complaints have had higher incidence of actinomycosis in their tonsillar tissue than others ($p = .03$, $p = .001$). There were 23 patients with tonsillar asymmetry; 9 from actinomycosis group and 14 from control group ($p = .33$). There was no significant difference between two groups regarding concomitant adenoid hyperplasia, tonsillar hypertrophy grading, tonsillar asymmetry and fibrosis of tonsillar tissue (Table. 1, 2).

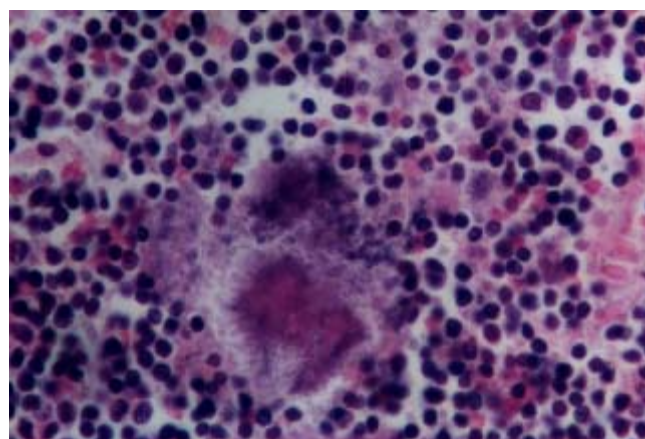


Figure 1. Histopathologic section of tonsil demonstrating a radial spoke like fashion appearance of a tonsillar actinomycosis (haematoxylin-eosin, original magnification 200 X)

DISCUSSION

Actinomycosis is a well-known infection reported in several anatomic locations of body, such as; oral cavity, pharynx, maxilla, mandible, temporal mandibular joint, neck, mediastinum, thyroid gland, salivary gland, middle ear and central nervous system.^{2,7} The ability to identify actinomycosis histologically is straightforward and has a higher yield than culture. Although culture is classically believed to be the most definitive means of identification, there are a high number of false negative results reported. This may be due to culture overgrowth by other organisms, failure of growth

following antibiotic therapy and failure of growth due to inadequate anaerobic conditions.⁶ Since the biopsy of infected tissues, including tonsils, has been shown to be diagnostic we have preferred to search tonsillar actinomycosis histopathologically instead of culturing.

The frequency of tonsillar actinomycosis was reported to be as high as 56 % in the literature [1]. The reason of great differences in frequency among several studies may be contributed to staining technique, indications for surgery and regional differences.³ Our study indicates that the *Actinomyces* in tonsillar tissue is a colonization; this may also explain the great differences in tonsillar actinomycosis incidence. Women are infected much less frequently than are men.² On the other hand, Gaffney et al.,³ have found no gender preponderance of the tonsillar actinomycosis in patients with RAT. Their study group was patients with RAT and control group was patients with the diagnosis other than tonsillitis. Age range was very different between two groups (2-34 years in study group and 27-80 years in control group). There was a female preponderance of tonsillar actinomycosis in our study. This may be explained by methodology of the study, environmental, cultural factors and/or women may be more susceptible to infection. Regional differences and environmental risk factors for colonization of tonsils with actinomycosis would also explain this difference. A correlation between actinomycosis and tonsillar hypertrophy has been proposed in a study conducted by Bhargawa et al.¹ Whereas, the indications for tonsillectomy were different in these studies.^{1,6} We have compared hypertrophy grading of tonsils in patients with the same surgical indications. Thus, the misleading effects of different surgical indications were eliminated in this study. We found no effect of actinomycosis on the tonsillar hypertrophy grading. High frequency of actinomycosis in patients operated on during summer session may be explained by colonization of oral cavity during this period of year. Harley⁸ found no statistically significant difference between patients with asymmetric and symmetric tonsils regarding to the presence of actinomycosis in tonsillar tissue. We had 23 patients with tonsillar asymmetry; 9 from actinomycosis group and 14 from control group. Our finding was correlated with that of Harley.⁸



During the course of actinomyces infection there is a characteristic woody type of fibrosis and suppuration.² In our study, however, there was no statistically significant difference between two groups with respect to tonsillar fibrosis. This also favors that; tonsillar actinomyces is a colonization of tonsils, not a disease process affecting the clinical course.

CONCLUSION

In contrary to some published studies, Actinomyces are saprophytic organisms in tonsillar tissue, unless it does not cause a fulminating disease such as abscess or cellulites. It does not play any role in tonsillar hypertrophy, fibrosis, asymmetry and concomitant adenoid hyperplasia.

REFERENCES

1. Bhargava, D., Bhusnurmath, B., Sundaram, KR., Raman R, Al Okbi HM, Al Abri R, Date A. 2001. Tonsillar actinomyces: a clinicopathological study. *Acta Tropica* 80, 163-168. (PMID: 11600096)
2. Richtsmeier, WJ., Johns, ME. Actinomyces of the head and neck. 1979. *CRC Crit Rev Clin Lab Sc.* 11, 175-202. (PMID: 389552)
3. Gaffney, R., Harrison, M., Walsh, M., Sweeney, E., Cafferkey, M. 1993. The incidence and role of actinomyces in recurrent acute tonsillitis. *Clin Otolaryngol* 18, 268-271. (PMID: 8877183)
4. Wiatrak, BJ., Woolley, AL. Pharyngitis and adenotonsillar disease. In: Cummings, CW., Frederickson, JM., Harker, LA., Krause, CJ., Richardson, MA., Schuller, DE (Es.), *Otolaryngology Head Neck Surgery*, vol. Pediatric, third ed., pp. St. Louis, Mosby, 1998:202-204..
5. Brodsky, L., Moore, L., Stanievich JF. 1987. A comparison of tonsillar size and oropharyngeal dimensions in children with obstructive adenotonsillar hypertrophy. *Int J Pediatr Otorhinolaryngol* 13, 149-156. (PMID: 3667094)
6. Pransky, SM., Feldman, JI., Kearns, DB., Seid, AB., Billman, GF. 1991. Actinomyces in obstructive tonsillar hypertrophy and recurrent tonsillitis. *Arch Otolaryngol Head Neck Surg* 117, 883-885. (PMID: 1892620)
7. Olson, TS., Seid, AB., Pransky, SM. 1989. Actinomyces of the middle ear. *Int J Pediatr Otorhinolaryngol* 17, 51-55. (PMID: 2707978)
8. Harley EH. 2002. Asymmetric tonsil size in children. *Arch Otolaryngol Head Neck Surg* 128, 767-769. (PMID: 12117331)